Fine needle aspiration study of the abdominal cutaneous and subcutaneous nodules

Shaweta Rana, MD[1]
Nisha Marwah, MD[2]
Promil Jain, MD[1]
Sumiti Gupta, MD[1]
Sanjay Marwah, MD[1]
Rajeev Sen, MD[1]

1. Department of Pathology, Pt BDS PGIMS, Rohtak, Haryana, India
2. Department of Surgery, Pt BDS PGIMS, Rohtak, Haryana, India

Corresponding Author:
Promil Jain, MD
Department of Pathology, Pt BDS PGIMS, Rohtak, Haryana, India
Email: jainpromil@gmail.com

Conflict of interest: none to declare

Background: Abdominal cutaneous and subcutaneous nodules are uncommon benign or malignant lesions. The majority of the malignant nodules are metastatic in origin and may be the initial presentation of a primary malignancy; hence, an early diagnosis is important. Our aim of this study was to find out the spectrum of lesions (both non-neoplastic and neoplastic) that present as cutaneous and subcutaneous nodules on the abdominal wall and to find out the efficacy of fine needle aspiration cytology in the early diagnosis of such lesions so that the need for histopathology can be minimized.

Method: The study was conducted on 46 patients of all age groups who presented with various palpable cutaneous and subcutaneous abdominal nodules. These nodules were assessed by fine needle aspiration cytology. The diagnosis was made cytopathologically and subsequently correlated with the histopathological diagnosis when possible.

Result: Out of 46 cases aspirated; there were 13 non-neoplastic cases, 15 benign neoplasms, 17 malignant cases and one case whose tissue sample was inadequate for opinion but turned out to be metastatic deposits from renal cell carcinoma on histopathology. The rate of unsatisfactory fine needle aspiration cytology was 2.2% and the sensitivity was 89.47%. The specificity and positive predictive value were 100%.

Conclusion: Fine needle aspiration cytology is a simple, minimally invasive, highly accurate and cost effective technique for early diagnosis of malignant metastatic nodules on the abdominal wall and therefore minimizes the need for histopathology and facilitates decision-making regarding the mode of treatment.

Keywords: cytology, cutaneous nodule, fine needle aspiration, subcutaneous tissue

Received: March 9, 2012
Accepted: August 3, 2012

Iran J Dermatol 2012; 15: 50-55

INTRODUCTION

Cutaneous and subcutaneous nodules of the abdominal region are uncommon. Although a variety of benign as well as malignant neoplastic lesions can be encountered, primary malignant cutaneous and subcutaneous tumors of the abdominal wall are very rare. The majority of malignant nodular lesions in the abdominal wall are metastatic tumors which may sometimes be the initial presentation of an underlying malignancy [1]. Fine Needle Aspiration Cytology (FNAC) is a simple, fast and inexpensive technique with high sensitivity and specificity and has proved to be very useful in quick confirmation of the nature of the lesion [2-4]. We planned the present study with

the aim of evaluating the efficacy of FNAC in early diagnosis of all these lesions so that histopathology could be avoided and the mode of treatment could be decided at the earliest.

PATIENTS AND METHODS

A total of 46 patients of both sexes and all age groups were aspirated for clinically diagnosed palpable nodules in the abdominal wall region. FNAC was performed in all the 46 cases as an outpatient procedure using a 22-23 gauge needle attached to a 20 cc plastic syringe without local anaesthesia. The lesion site was cleaned using the Povidone-Iodide solution and ethyl alcohol. Aspirates from different parts of the nodule were collected by alternating the direction of the needle inside the nodule and giving multiple passes. Both air dried and alcohol fixed smears were prepared and stained by May-Grunwald Giemsa and Hematoxylin & Eosin using standard procedures [5,6]. Whenever needed, special stains such as mucicarmine and Periodic Acid Schiff were applied. Detailed history, clinical examination and relevant investigations of all patients were recorded. The diagnosis was made cytopathologically and subsequently correlated with the histopathological diagnosis when possible.

RESULTS

The study included cases with an age range of 5 to 82 years. The majority of the participants belonged to the age group 41-50 and male patients outnumbered female patients with a ratio of 7.5: 4. In our study, forty six cases were aspirated from palpable cutaneous and subcutaneous nodules of the abdominal region including thirty six cases from the abdominal wall, seven cases from the paraumblical region, and three cases from the umbilical region (Table 1). Thirteen non-neoplastic cases included ten inflammatory lesions, two cystic

Table 1. Cytological spectrum of cases in abdominal wall nodules with histological correlation (n=46)

Type of lesion on FNAC	No of cases	Histological diagnosis		Biopsy not available	Unsatisfactory FNAC
		Consistent	Inconsistent		
ABDOMINAL WALL NODULES	36				
Non neoplastic	10	09			
Inflammatory					
Parasitic cyst	4	4			
Acute inflammatory lesion	3	3		1	–
Benign cystic lesion	2	2			
Endometriosis	1	1			
Neoplastic	25	22			
Benign					
Lipoma	14	12		2	
Neurilemmoma	1	–	1 (MPNST)		–
Malignant					
Metastatic carcinoma	10	10			
Inadequate for opinion	1				1
PARAUMBILICAL REGION	7				
Non neoplastic	3	2			
Inflammatory					
Parasitic cyst	2	2			
Acute inflammatory lesion	1		1 (SCC)		
Neoplastic	4	4			
Malignant					
Metastatic carcinoma	4	4			
UMBILICAL	3				
Non neoplastic	0	0			
Neoplastic	3	3			
Malignant					
Metastatic carcinoma	3	3			
TOTAL	46	40	2	3	1

MPNST-Malignant peripheral nerve sheath tumour; SCC- Squamous cell carcinoma.

lesions and one case of endometriosis (Figure 1). Out of thirty two neoplastic lesions, fifteen were benign and seventeen were malignant. The fifteen benign neoplasms included fourteen cases of lipoma and one case of spindle cell tumor on FNAC. All the malignant cases were metastatic carcinomas including ten cases of metastatic deposits from adenocarcinoma, five from squamous cell carcinoma and two from poorly differentiated carcinomas. All the three nodules on umbilicus were metastatic nodules.

Twelve out of seventeen metastatic nodules were from internal carcinoma. The diagnosis of the primary site was made radiologically with cytological and histopathological examination. The ovary was the most frequent site for primary malignancy (n=3) while the other sites of primary malignancy which gave rise to metastatic deposits were the kidneys (n=2), cervix (n=2), pancreas (n=2), oesophagus (n=1), gall bladder (n=1), and urinary bladder (n=1).

Cytopathological and histopathological correlation was available in forty three cases. Biopsy was not available for three cases. Table 1 shows the cytological spectrum of the cases in abdominal wall nodules along with their histopathological correlation. Out of forty three cases, all seventeen cases diagnosed to be malignant on FNAC proved to be malignant on biopsy and one case who was inadequate for opinion cytologically was later diagnosed as metastatic deposits from high grade renal cell carcinoma on histopathology. No false positivity was reported. Out of fifteen benign cases, biopsy was not done in two cases. Out of thirteen benign cases, cytological diagnosis was consistent in eleven cases. One case of neurilemmoma turned out to be malignant peripheral nerve sheath tumour on biopsy (Figure 2) with false negativity of 7.69% and biopsy was not available

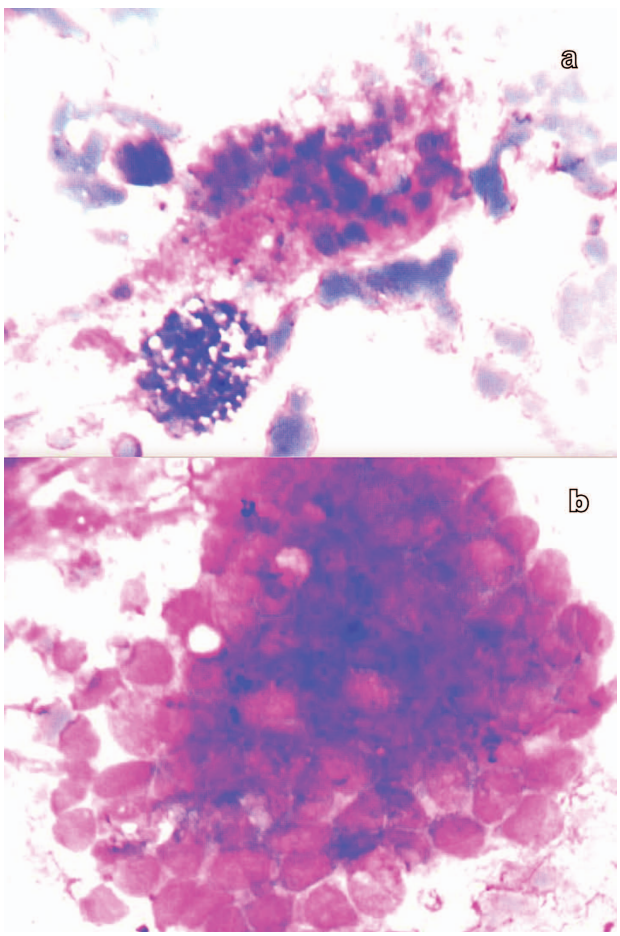

Figure 1. Endometriosis- FNAC smear a) Giemsa; 100×; b) Giemsa; 400×

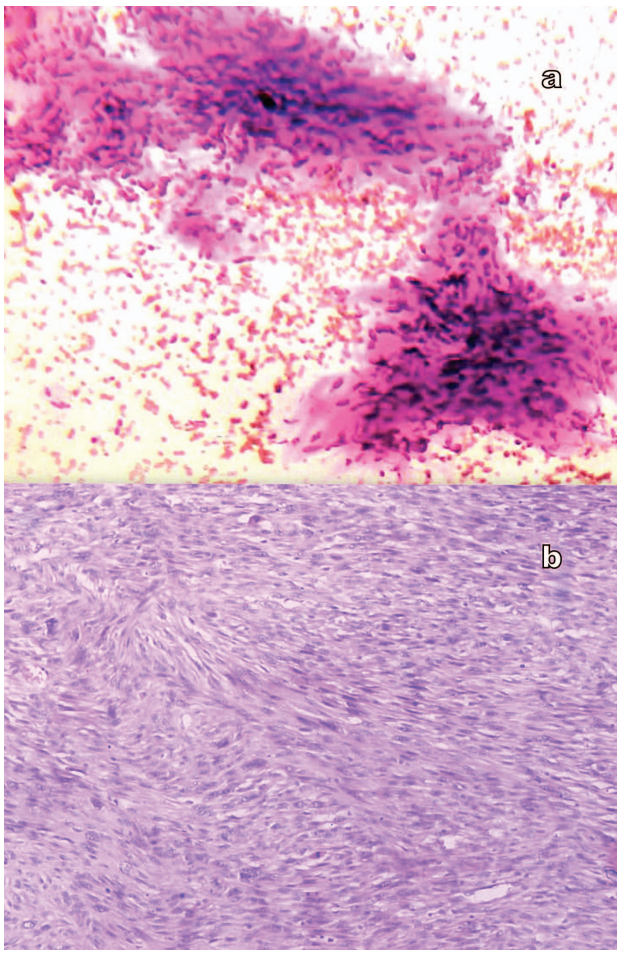

Figure 2. a) Neurilemmoma: on FNAC, smear showing cohesive tissue fragments, spindle shaped palisading nuclei in the fibrillar background (Giemsa; 100×); b) Malignant peripheral nerve sheath tumour on biopsy (H & E 100×)

in one case of acute inflammatory lesion which responded well to antibiotics and the swelling subsided. Of the thirteen non-neoplastic cases, eleven cases were histologically consistent. Out of the ten inflammatory lesions, six cases were found to be parasitic cysts on histopathology as were diagnosed on FNAC (Figure 3). Of the four acute inflammatory lesions diagnosed cytologically, biopsy was not available in one case, and another case who was diagnosed with an acute inflammatory lesion in the paraumbilical region proved to be squamous cell carcinoma on histopathology (false negativity=8.33%). Both of the non inflammatory cystic lesions also turned out to be cysticercosis. Total false negativity reported in our study was 16.02%, sensitivity was 89.47% and the specificity/ positive predictive value was 100%.

DISCUSSION

The majority of palpable nodular lesions in the abdominal wall are metastatic tumors originating from intra abdominal, pelvic and retroperitoneal organs. The overall incidence of cutaneous and subcutaneous metastasis has been reported to range from 0.7% to 10%. Although any region of skin can be involved, metastasis generally tends to occur close to the site of the primary malignancy [7,8]. Umbilical metastases from intra-abdominal carcinomas are well documented and often represent the first sign of underlying advanced malignancy with dismal prognosis; hence, an early diagnosis is important [9].

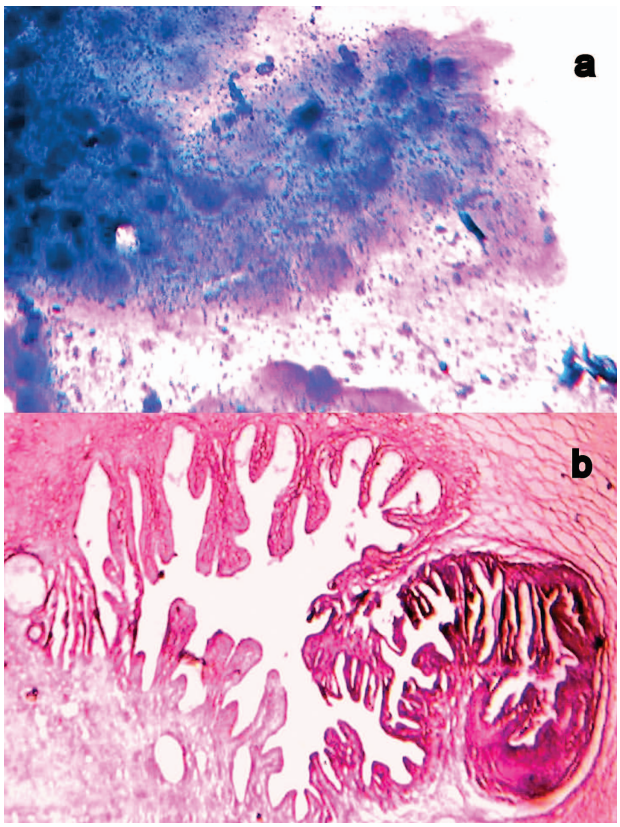

Figure 3. Cysticercosis: a) FNAC smear- Bladder wall fragment of cysticercus cellulosae (Giemsa; 100×) b) Tissue section (H&E; 400×)

In this essay, FNAC was performed in a total of forty six cases, including thirty six cases from the abdominal wall, seven cases from the paraumbilical and three cases from the umbilical region. The present study included 30 males and 16 females of all ages ranging from 5 to 82 years (mean age: 43.5 years). It was observed that the patients who had benign and non-neoplastic lesions were relatively younger than malignant cases. With advancing age, the malignant lesions outnumbered the non-neoplastic and benign lesions. More than 80% of cases over the age of sixty were malignant.

Smears were adequate in forty five cases. One case of inadequate aspirate turned out to be metastatic deposits from high grade renal cell carcinoma on histopathological examination. As high grade renal cell carcinomas are highly vascular, the repeated aspirates yielded abundant blood. Inadequacy in other series has also been attributed to either the lesion being cystic or vascular or to small fibrotic lesions where the cells are difficult to aspirate [10,11].

Out of forty six cases aspirated, there were thirteen non-neoplastic cases including ten inflammatory, two cystic lesions without inflammation and one case of endometriosis. As both of the non inflammatory cystic lesions also turned out to be cysticercosis, these lesions should be included in the differential diagnosis of nodular lesions as also emphasised by Patnayak et al [12]. The fifteen benign neoplasms included fourteen cases of lipoma and one case of neurilemmoma.

All the 17 malignant cases were metastatic carcinomas including 10 cases of metastatic deposits from adenocarcinoma, 5 from squamous cell carcinoma and 2 from poorly differentiated carcinoma. All the cases of umbilical and paraumbilical nodules in our study were metastatic deposits from adenocarcinoma, except for one case of squamous cell carcinoma. Similar observations have been reported in other studies [1,9]. The primary sites in the majority of the cases were intra-

abdominal/ pelvic as also observed by David et al [1]. The occurrence of cutaneous metastases from malignant neoplasms is seen from 1% to 9% of individuals as determined on autopsy. Umbilical involvement is uncommon and represents only 10% of all secondary tumors which have spread to the skin [13].

"Sister Mary Joseph's nodule" is the eponym used for metastatic involvement of the umbilicus. The umbilical nodule may be the presenting symptom in patients with internal malignancies or it may represent a late finding in patients with a widespread disseminated disease. An apparently insignificant umbilical nodule may be the only manifestation of an underlying advanced malignant disease and therefore clinicians should be aware of such nodules [14]. The umbilicus is an easy target for metastasis from an intra-abdominal tumour because of its variation in vascularity and embryological development. Spread may either be contiguous, from intraperitoneal metastasis via the portal vein or retrograde lymphatic flow from inguinal lymph nodes [15,16]. Rarely, metastasis may be from the prostate, ovaries, lungs, breast, haematopoietic malignancy, etc [9,17,18].

The observation made in various other studies in the past that the metastatic deposits usually occur close to the region of the primary growth was also confirmed by our study [4,19,20]. Most of the abdominal wall and umbilical metastases were from intra abdominal/pelvic organs. The factors which contribute to this pattern are poorly understood. In general, spread of the tumor to the regional skin is thought to be via the lymphatic route, while metastases distant from the primary site are due to hematogenous spread [4].

All the studies including ours have underlined the utilization of FNAC in the diagnosis of umbilical and abdominal metastatic nodules and decision-making for further investigations. However, it is also important to keep in mind that benign lesions such as endometriosis, fibroma, keloid, epidermal inclusion cysts or other non specific umbilical cysts may rarely present as an umbilical nodule and are called Pseudo Sister Mary Joseph's nodules [9,14,20,21]. There were 2 false negative cases but no false positive case in our study. The sensitivity of our study was 89.47% while its specificity and positive predictive value was 100%.

To conclude, FNAC of cutaneous and subcutaneous nodules of the abdominal wall plays an important role in rapid confirmation of the diagnosis and avoiding unnecessary surgical intervention in the majority of cases. It is a valuable tool in detecting metastasis from known and unknown primaries and in the follow-up of the tumour recurrence. Diagnosis of cutaneous metastases can be made easily and promptly because skin lesions often mimic the primary tumour cytologically. Adequate FNA sampling and sufficient cellularity with preserved cytomorphological details are prerequisites for avoiding false negative results.

REFERENCES

1. David O, Kluskens L, Reddy V, Gattuso P. Malignant cutaneous and subcutaneous abdominal wall lesions: a fine needle aspiration study. Diag Cytopathol 1998; 19: 267-9.
2. Parate SN, Sankalecha SM, Anshu M, et al. Utility of fine needle aspiration cytology in skin tumours. J Cytol 2003; 20: 180-4.
3. Daskalopoulou D, Galanopoulou A, Statinopoulou P, et al. Cytologically interesting cases of primary skin tumors and tumor-like conditions identified by fine needle aspiration biopsy. Diag Cytopathol 1998; 19: 17-28.
4. Srinivasan R, Ray R, Nijhawan R. Metastatic cutaneous and subcutaneous deposits from internal carcinoma. Acta Cytol 1993; 37: 894-8.
5. Inwood MJ, Thomson S. Basic hematologic techniques. In: Raphael SS, editor. Lynch's medical laboratory technology. 3rd ed. Philadelphia: WB Saunders; 1976: 1073-129.
6. Culling CFA. Histology. In: Raphael SS, editor. Lynch's medical laboratory technology. 3rd ed. Philadelphia: WB Saunders; 1976: 916-33.
7. Lookingbill DP, Spangler N, Helm KF. Cutaneous metastatic carcinoma: a retrospective study of 4020 patients. J Am Acad Dermatol 1993; 29: 228-36.
8. Rosen T.Cutaneous metastases. Med Clin North Am 1980: 65: 885-900.
9. Sahai K, Kapila K, Verma K. Fine needle aspiration cytology of umbilical nodules: "Sister Joseph's nodule." Diag Cytopathol 2001; 25: 309-10.
10. Layfield LJ, Glasgow BJ. Aspiration biopsy cytology of primary cutaneous tumors. Acta Cytol 1993; 37: 679-88.
11. Spitz DJ, Reddy V, Selvaggi SM, et al. Fine needle aspiration of scalp lesions. Diag Cytopathol 2000; 23: 35-8.
12. Patnayak R, Kalyani D, Rao IS, et al. Cysicercosis: The hidden parasite with short review of literature. Internet J Infect Diseases 2007; 6(1).
13. Raimondo G, Marco C, Federico E, Mario B. Umblical metastases: current viewpoint. World J Sur Oncol 2005; 3:13 doi: 10.1186/1477-7819-3-13.

14. Aich RK, Karin MR, Chakraborty B, et al. Sister Mary Joseph's Nodule. Indian J Med Paediatric Oncol 2008; 29: 40-3.
15. Edoute Y, Malberger E, Kuten A. Umbilical metastasis diagnosed by fine needle aspiration. J Surg Oncol 1990; 45: 56-8.
16. Handa U, Garg S, Mohan H. Fine needle aspiration cytology of Sister Mary Joseph's (Paraumbilical) nodules. Diag Cytopathol 2008; 36: 348-50.
17. Deb P, Rai RS, Rai R, et al. Sister Mary Joseph's nodule as the presenting sign of disseminated prostate carcinoma. J Cancer Res Ther 2009; 5: 127-9.
18. Shukla P, Gupta D, Bisht SS, Pant MC. Ovarian adenocarcinoma in a young female with skin and umblical metastasis. Indian J Med Paediatric Oncol 2009; 30: 144-6.
19. Gupta RK, Naran S. Fine needle aspiration cytology of cutaneous and subcutaneous metastatic deposits from epithelial malignancies. Acta Cytol 1999; 43: 126-30.
20. Reyes CV, Jensen J, Eng AM. Fine needle aspiration cytology of cutaneous metastases. Acta Cytol 1993; 37: 142-8.
21. Fratellone PM, Holowecki MA. Forgotten node: A case report. World J Gastroenterol 2009; 15: 4974-5.