A young girl with H syndrome and coeliac disease

Armaghan Gharehaghaji Zare, MD
Afsaneh Radmehr, MD
Faranak Ghasemi, MD*

Department of Dermatology, Faculty of Medicine, Tabriz University of Medical Sciences, Tabriz, Iran

**Corresponding author:*
Faranak Ghasemi, MD
Department of Dermatology, Faculty of Medicine, Tabriz University of Medical Sciences, Tabriz, Iran
Postal code: 5163639888
Email: fghasemi072@gmail.com

Received: 8 June 2019
Accepted: 20 Feb 2020

H syndrome is an autosomal recessive genodermatosis with reports dating back to the last decade. This syndrome is caused by mutations in the SCL29A3 gene. The clinical characteristics of this syndrome consist of dermatological manifestations, including hyperpigmented, hypertrichotic, and indurated patches and plaques. It affects various systems by causing heart anomalies, hepatosplenomegaly, hypogonadism, and low height.

This is the case of a 19-year-old girl from the northwest of Iran who was born of a cousin marriage. The primary manifestations included low height, underdeveloped secondary sex characteristics, and typical dermatological manifestations. This patient was examined mostly because of digestive and endocrine problems and thus had not been subject to extensive dermatological examinations until the skin biopsies mirrored manifestations similar to histiocytoses (e.g., Rosai-Dorfman disease and granuloma annulare). The patient was eventually diagnosed with H syndrome by a dermatologist from the clinical symptoms.

H syndrome is an autosomal recessive genodermatosis that affects different organs and is diagnosed by a set of typical and systemic cutaneous symptoms and biopsies. In this patient, an endoscopic examination of the upper gastrointestinal tract was carried out due to reports of anemia. A biopsy of the atrophic duodenum region revealed the existence of coeliac disease. However, the comorbidity of coeliac disease and H syndrome has not been previously reported.

Keywords: hyperpigmentation; hypertrichosis; hypogonadism

Iran J Dermatol 2020; 23: 35-39

INTRODUCTION

H syndrome was originally defined in 2008 [1]. H syndrome is an autosomal recessive genodermatosis with systemic manifestations. Hyperpigmented, hypertrichotic, and indurated patches and plaques comprise the cutaneous pathognomonic characteristics of this condition and form its hallmark. Generally appearing on the inner thighs, these patches and plaques cause prevalent disorders in different systems such as low height (short stature), hepatosplenomegaly, hearing loss, heart anomalies, hypogonadism, hyperglycemia/diabetes mellitus, skeletal anomalies (fixed flexion contractures, hallux valgus), etc [1,2].

H syndrome is a rare autosomal recessive disorder caused by mutations in the SLC29A3 gene. This gene encodes the human nucleoside transporter (hENT3) of the ENT3 family [3]. Given the various manifestations of H syndrome, it can be wrongly diagnosed. Hence, having further knowledge of this syndrome is important. This patient was a case from the northwest of Iran that was reported due to the rarity of this disease and the diversity of the symptoms.

CASE PRESENTATION

A single 19-year-old girl, the third child of a healthy couple in a cousin marriage, visited the

dermatology clinic of Sina Hospital (Tabriz, Iran) with complaints about cutaneous conditions that had manifested as progressive hyperpigmented patches and plaques as well as hypertrichosis and induration on the arms and thighs from the age of 2. This patient was born as a full-term neonate through natural childbirth at home. The mother received no prenatal care, and no post-birth examination of the neonate's health and gender were carried out. The other two children in this family had no similar conditions nor do they had a history of specialized diseases. The assessment of the patient's growth indicators at the health center revealed height and weight growth retardation considering the patient's age. For instance, at the age of 6, her height and weight were 97 cm and 16.5 kg, respectively (chronologic age: 6 years and 10 months; height age: 3 years and 3 months, and weight age: 3 years and 8 months). Hyperpigmented patches manifested symmetrically with hypertrichosis and mild induration on the inner thighs and arms at the age of 2. The condition progressed slowly and gradually from the age of 2, spreading to the anterior and posterior sides of the patient's trunk. The patient had been subjected to pubertal induction for 4 years using 0.625 mg conjugated estrogens due to a lack of secondary sex characteristics and primary amenorrhea at the age of 15. However, the treatment did not change the manifestation of the secondary sex characteristics, and the patient had also been diagnosed with hypogonadotropic hypogonadism.

CLINICAL FINDINGS

The physical examination revealed the presence of plaques with hyperpigmented and indurated centers and hypertrichotic patches with erythematous irregular margins on the chest, abdomen, and back along the spinous process and proximal to the upper and lower limbs, with the knees being spared (Figure 1). These conditions were asymptomatic.

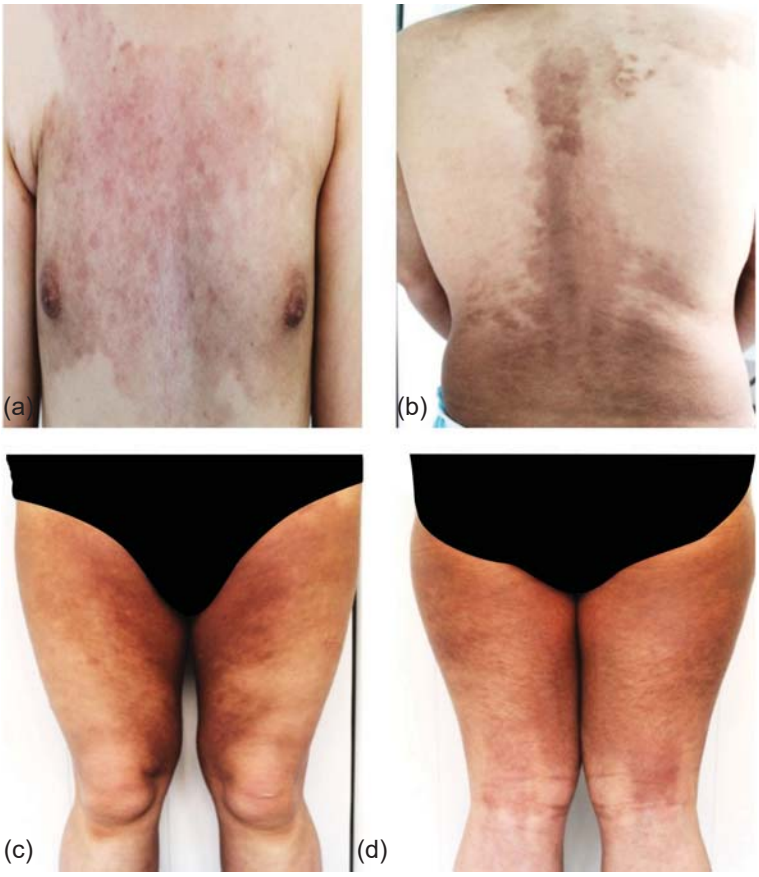

Figure 1. Clinical findings: Symmetrical hyperpigmented, hypertrichotic skin lesions on the chest wall (a), back (b), front side of thighs (c), and back side of thighs (d).

The patient had a normal karyotype (normal female, 46xx) and normal mental capacity. She also had normal vital signs. A cardiac auscultation revealed a decrease in the heart sounds and a high heart rate (90 <). A 2×2cm lymph node and a scar on the right axillary lymph node were observed in the lymph nodes examination. Her thelarche was in Tanner I stage (prepubertal). In an abdominal examination, the liver was felt 4 cm below the coastal margin. In a genital examination, large and indurated labia majora were recorded, and the pubis region was indurated; there was also no vaginal opening. A skeletal examination indicated a short stature (height: 138 cm, and weight: 40 kg), hallux valgus, and lateral tibial torsion.

Since the patient suffered from hypochromic microcytic anemia, an endoscopic examination of the upper gastrointestinal tract was carried out, revealing duodenal mucosal atrophy (D1, D2). Coeliac disease was also found through biopsies. The MRI (with and without contrast) results showed a normal pituitary gland. In ultrasonography, the uterus and ovaries were found to be normal. In the abdomen and pelvis ultrasound assessments, the liver span was 142cm, but the spleen was oversized (span = 142). An examination of the kidneys showed mild hydronephrosis, and cardiomegaly was observed in the CXR. The echocardiography showed right atrium hypertrophy (RAH), right ventricular hypertrophy (RVH), and pulmonary hypertension. Trans-esophageal echocardiograph (TEE) results confirmed the following cardiac conditions: lipomatous hypertrophic change of IAS (inter-atrial septum) cystic mass anterior to PA, most interrupted IVC probably with lung origination without connection to cardiac chamber, and RVH.

Considering the patient's cutaneous manifestations, several differential diagnoses were considered, such as Winchester syndrome, hemochromatosis, POEM's syndrome, Beker's nevus, and morphea. Consequently, the patient underwent a skin biopsy based on these differential diagnoses. The histopathologic evaluation showed widespread fibrosis with proliferation of histiocytes between normal and necrotic collagen bundles and acanthosis with basal layer hyperpigmentation in the epidermis, similar to granuloma annulare and Rosai-Dorfman disease (Figure 2) (Tables 1-3).

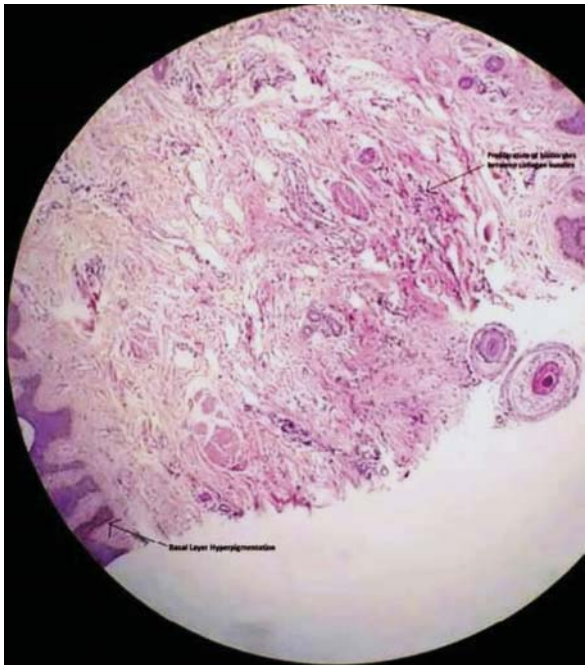

Figure 2. Proliferation of histiocytes between collagen bundles; basal layer hyperpigmentation (×40)

Table 2. Classification of common clinical findings by the rate of prevalence about patients with H syndrome based on a study of 79 patients [2]

Clinical findings	Prevalence
Cutaneous hyperpigmentation accompanied by hypertrichosis and induration	68%
Flexion contractures of the fingers and toes	56%
Sensorineural hearing loss	53%
Short stature	49%
Hepatomegaly	43%
Splenomegaly	39%

Table 1. Results of paraclinical tests for the patient

Test	Results	
CBC (Complete blood count)	Hb:9.8, serum iron:23, MCH:20.3	Anemia
Serology	Anti EMA IgG:143, Anti Giliadin (IgG)>100, TTG (IgG):3.5, ESR:80-100	Increased
Endocrinology	FSH: 6.3, LH: 11.9, Testosterone: 0.09, Estradiol: 50.7	Normal
Thyroid function test	TSH: 2.3, FT4:8.7	Normal
Liver function test	SGOT (AST):9, SGPT (ALT):12, T.Billi:0.5, D.Bili:0.1	Normal
Lipid profile	HDL: 29, Cholesterol:115, Triglyceride:132	Normal

Table 3. Clinical findings of our patient

Findings	Clinical manifestations in current patient
Cutaneous	Cutaneous hyperpigmentation with hypertichosis and induration on upper and lower limbs, abdomen, back, buttoks
Musculoskeletal	Hallux valgus, lateral tibial torsion, short stature (138cm)
Cardiovascular	RVH, RAH, pulmonary hypertension, cardiomegaly, lipomatous hypertrophic change of IAS
Hematological	Axillary lymphadenopathy, splenomegaly
Endocrine	Hypogonadism

RVH: Right ventricular hypertrophy
RAE:Right atrial enlargement
IAS:interatrial septum

DISCUSSION

Most reported cases of H syndrome are in Middle Eastern countries although there are reports of this syndrome in other parts of the world [2]. The determining factor in the discovery of the cause of H syndrome was the mutation in SLC29A3, which encodes protein hENT3. This protein belongs to the ENT3 family, which plays a major role in the mitochondrial membrane and functions of these organelles [3].

The patient was suffering from hypochromic and microcytic anemia and was diagnosed with coeliac disease through endoscopy of the upper gastrointestinal tract; serologic measurements also showed increased levels in anti-Giliadin (IgG) (> 100) and TTG (IgG) (:3.5). This condition was improved by a gluten-free diet. Various degrees of anemia have been reported in other H syndrome patients, and one patient was diagnosed with immune hemolytic anemia [4].

IDDM and hearing loss may occur at early ages prior to the onset of cutaneous conditions [5,6]. However, this patient did not suffer from hearing loss or diabetes mellitus. Previous studies have shown a wide range of cardiac conditions in H syndrome patients: ASD (atrial septal defect), VSD (ventricular septal defect), MVP (mitral valve prolapse), cardiomegaly, pulmonary hypertension, left ventricular dilation [1], acute coronary syndrome [7], pericarditis, left superior vena cava, pericardial effusion, and pulmonary stenosis [3,8]. The diversity of the heart anomalies in H syndrome patients mirrors the role hENT3 plays in the normal function and structure of the heart [9]. Regarding the heart anomalies, pericardial conditions are the most prevalent cardiovascular anomalies in patients with H syndrome [2]. However, this patient was not diagnosed with any pericardial condition, but lipomatous hypertrophy of IAS was diagnosed, which has not previously been reported as a prevalent cardiac condition among H syndrome patients. H syndrome is a new form of histiocytosis, and it is considered a histiocytic genodermatosis [5]. From a histopathological point of view, H syndrome is similar to Rosai-Dorfman disease; patients always have high ESR and histiocytic pathologic results [5]. In a biopsy of the cutaneous lesions caused by Rosai-Dorfman, dermal infiltration of large histiocytes was observed along with lymphocytes, plasma cells, and several neutrophils [10]. In addition, histopathological assessments of the cutaneous lesions in H syndrome cases revealed the widespread fibrosis in the derm and subcutaneous fat as well as cells similar to histiocytes with irregular nuclei and nodular aggregation of lymphocytes and scattered plasma cells [11]. A comparison has been drawn between the clinical symptoms and histopathologic characteristics of these two diseases in another study [10] (Table 4).

CONCLUSION

H syndrome must be taken seriously in patients with typical cutaneous manifestations, disorders in various organs, and endocrine pathologies. The symptoms of H syndrome range from mild to severe. This condition is difficult to diagnose due to similarities between this syndrome and diseases with similar symptoms (especially with similar cutaneous manifestations). In this patient, typical cutaneous manifestations, short stature, delayed puberty, and hypogonadism were indicative of H syndrome. She had developed anemia due to malabsorption caused by coeliac disease. Therefore, considering the multiple reports of anemia in this patient, if endoscopic examinations had been conducted, perhaps coeliac disease would have been considered the cause of anemia and the resulting

Table 4. Comparison of clinical and histopathologic features of familial Rosai-Dorfman disease and H syndrome [10]

Tissue	Familial Rosai-Dorfman Disease	H syndrome
Inheritance	Autosomal recessive	Autosomal recessive
Skin	Hyperpigmentation of lower extremities	Hyperpigmentation and indurated hypertrichotic patches on the lower abdomen and lower extremities
Heart	Atrial septal defect	Pulmonary stenosis, patent ductus arteriosus
Ear	Sensorineural deafness	Sensorineural deafness
Abdomen	Hepatosplenomegaly	Hepatosplenomegaly
Growth	Short stature	Short stature
Endocrine	-	Diabetes mellitus Hypogonadism Gynecomastia
Eye	Uveitis, eyelid swellings	Exophthalmos
Hands	-	Camptodactyly, flexion contractures
Feet	-	Hallux valgus fixed flexion contractures of toe joints
Hematological anomalies	Bone marrow showing nonclonal myeloproliferative process, with numerous monocytes and histiocytes and moderate myelofibrosis	Red cell aplasia due to myelofibrosis
Lymph nodes	Cervical, submandibular, inguinal lymphadenopathy	-

diagnosis of H syndrome might not have occurred. This report is an attempt to increase awareness in medical practice about different manifestations of H syndrome.

Acknowledgment

We thank the patient and her family for their participation in this study.

Conflict of Interest: None declared.

REFERENCES

1. Molho-Pessach V, Agha Z, Aamar S, et al. The H syndrome: a genodermatosis characterized by indurated, hyperpigmented, and hypertrichotic skin with systemic manifestations. J Am Acad Dermatol. 2008;59(1):79–85.
2. Molho-Pessach V, Ramot Y, Camille F, et al. H syndrome: the first 79 patients. J Am Acad Dermatol. 2014;70(1):80–88.
3. Molho-Pessach V, Lerer I, Abeliovich D, et al. The H syndrome is caused by mutations in the nucleoside transporter hENT3. Am J Hum Genet. 2008;83(4):529-534.
4. Nasimfar A, Sanaei Dashti A, Haghbin H. A child with H syndrome. Arch Pediatr Infect Dis. 2016;4(2): e28321.
5. Tekin B, Atay Z, Ergun T, et al. H syndrome: a multifaceted histiocytic disorder with hyperpigmentation and hypertrichosis. Acta Derm Venereol. 2015;95(8):1021–1023.
6. Ramot Y, Sayama K, Sheffer R, et al. Early-onset sensorineural hearing loss is a prominent feature of H syndrome. Int J Pediatr Otorhinolaryngol. 2010;74(7):825–827.
7. Shankarappa RK, Ananthakrishna R, Math RS, et al. Accelerated coronary atherosclerosis and H syndrome. BMJ Case Rep. 2011;2011:bcr0320114019.
8. Doviner V, Maly A, Ne'eman Z, et al. H syndrome: recently defined genodermatosis with distinct histologic features. a morphological, histochemical, immunohistochemical, and ultrastructural study of 10 cases. Am J Dermatopathol. 2010;32(2):118–128.
9. Mutlu GY, Ramot Y, Babaoglu K, et al. Agenesis of the inferior vena cava in H syndrome due to a novel SLC29A3 mutation. Pediatr Dermatol. 2013;30(5):e70–e73.
10. Colmenero I, Molho-Pessach V, Torrelo A, et al. Emperipolesis. Am J Dermatopathol. 2012;34(3):315–320.
11. Dias-Polak D, Indelman M, Bergman R, Avitan-Hersh E. The histopathology and phenotypic variability in H syndrome. Clin Case Reports. 2018;6(3):476–478.