

Therapeutic effect of bleomycin tattooing combined with trichloroacetic acid and shaving on treatment-resistant plantar warts

Ali Asilian, MD ^{1,2}

Zabihollah Shahmoradi, MD ^{1,2*}

Shahryar Rahmani, MD ³

Hossein Hafezi, MD ^{1,2}

Samaneh Mozafarpour, MD ^{1,2}

1. *Department of Dermatology, School of Medicine, Isfahan University of Medical Sciences, Isfahan, Iran*

2. *Skin Diseases and Leishmaniasis Research Center, School of Medicine, Isfahan University of Medical Sciences, Isfahan, Iran*

3. *School of Medicine, Isfahan University of Medical Sciences, Isfahan, Iran*

*Corresponding author:

Zabihollah Shahmoradi, MD
Dermatologist; Department of dermatology; School of Medicine, Isfahan University of Medical Sciences, Isfahan, Iran
E-mail: shahmoradi@med.mui.ac.ir

Received: 22 June 2020

Accepted: 02 September 2020

Background: Bleomycin is used for the treatment of warts. However, only its injected form can be used due to systemic use side effects, and plantar warts have a high recurrence rate following administration of bleomycin tattooing alone. To find an effective alternative with fewer side effects, we decided to investigate the effectiveness of bleomycin tattooing combined with trichloroacetic acid (TCA) and shaving in the management of treatment-resistant plantar warts.

Methods: The patients with treatment-resistant plantar warts entered the present quasi-experimental study. the wart site was shaved ahead of bleomycin tattooing and TCA peeling. This treatment was provided at one-month intervals and was repeated a maximum of four times. Patients were followed for six months after completion of the therapy. Finally, the patients' data were completed according to photographs (monthly photos taken of lesions) and careful examinations.

Results: The present study involved 56 patients with a mean age of 25.75 ± 12.22 years. Twelve patients (21.4%) recovered after the first treatment; 14 (25%) needed the second treatment, 12 (21.4%) needed the third, 10 (17.9%) the fourth, and eight (14.3%) did not recover after the fourth treatment. The recovery rate was 21.4% with one, 45.4% with two, 66.8% with three, and 85.7% with four treatment sessions.

Conclusion: The combination treatment of bleomycin plus TCA and shaving led to a remarkable recovery from treatment-resistant plantar warts (21.4% recovery with the first treatment session and up to 85.7% recovery after four sessions). The treatment included tattooing and local injections, leaving few side effects.

Keywords: bleomycin, trichloroacetic acid, warts

Iran J Dermatol 2021; 24: 102-109

DOI: [10.22034/ijdd.2020.235939.1147](https://doi.org/10.22034/ijdd.2020.235939.1147)

INTRODUCTION

Warts are benign epidermal neoplasms caused by human papillomaviruses (HPVs), which are tiny viruses with double-stranded and ring-shaped DNA. There are more than 100 different types

of HPVs. HPVs infect epithelial cells of the skin, mouth, esophagus, larynx, trachea, and conjunctiva, giving rise to both benign and malignant lesions. They induce a variety of infections. Common warts (verruca vulgaris) begin as smooth, flesh-colored papules and evolve into dome-shaped,

gray-brown, hyperkeratotic growths with black dots on the surface ^{1,2}.

Warts are highly prevalent and affect up to a third of primary school children ³. They often cause discomfort, making 2% of the general public and 6% of school-age children visit their family physicians every year ⁴.

Warts on the feet are called plantar warts and are caused by HPV types 1, 2, 3, 4, 27, 29, and 57, often in points of maximum pressure such as the metatarsal heads or the heel ⁵. Plantar warts initially appear as tiny translucent papules, but rapidly turn into well-defined round lesions and rough keratotic surfaces enclosed by a thick horny layer ⁶.

The conventional treatment of warts involves cryotherapy by liquid nitrogen or occasionally topical salicylic acid ⁷. Other treatments include surgery, electrocautery, topical agents such as cantharidin, podophyllin, tretinoin, and imiquimod, as well as laser surgery ⁷. All these methods entail pain, post-inflammatory hypopigmentation, and recurrence. Factors affecting the choice of treatment include the size, number, and site of warts, the participant's priorities, the cost, comfort, adverse effects, and the therapist's experience ⁸. Bleomycin is a cytotoxic agent used in systemic chemotherapy but has been recognized and applied as a therapy for warts for around 40 years. Bleomycin is a complex of related glycopeptide antibiotics from *Streptomyces verticillus*. It inhibits DNA metabolism and is used as an antineoplastic, especially for solid tumors ⁹. Intralesional bleomycin has been used to treat various skin conditions such as hemangiomas, vascular malformations, telangiectasias, lesions of leishmaniasis cutis, and several types of cutaneous malignancies. It has also been used in the treatment of warts with varying degrees of success ¹⁰. Systemic bleomycin is rapidly metabolized in all body organs except the lungs and skin, and its toxic complications often lead to skin and mucosal toxicity, namely stomatitis, alopecia, hyperpigmentation, and occasionally pulmonary fibrosis ¹¹. Given these side effects, it is not wise to treat warts with systemic bleomycin; therefore, intralesional injection of bleomycin is recommended, which is also effective in treatment-resistant warts ^{5,12,13}. The intralesional injection of bleomycin can be used for treatment-resistant warts ¹⁴. As the first line of treatment, bleomycin is effective on multiple warts, especially the mosaic

variant ¹⁵. The best treatment response has been observed in common warts and periungual warts, while plantar warts showed the worst response ¹⁶. However, due to its local complications including severe pain, necrosis ^{17,18}, vasospasm, and Reynaud's phenomenon ¹⁹, a method with fewer complications should be sought. Hence, tattooing was proposed as a method with the least complications ²⁰. However, tattooing alone was not much effective for plantar warts, and treatment failure was reported in 37.5% of cases, with a high rate of recurrence ²⁰. Thus, we decided to benefit from the synergistic effects of several treatment modalities, one of which was the use of trichloroacetic acid (TCA).

TCA and mono-chloric acid (MCA) are organic acids that destroy warts via the chemical coagulation of proteins. Although this modality is extensively used, it has not been fully investigated. Cengiz reported a similar effect but fewer side effects for TCA compared to cryotherapy in verruca plana ⁸.

Various treatment modalities exist for warts, but none can eradicate lesions alone. Microsurgery shaving is another treatment. The surgical approach is less effective as a long-term treatment because residual virus-infected cells that have not been cleared by the host's immune system increase the likelihood of recurrence ²¹. However, its combined effect with bleomycin tattooing and TCA has not been investigated.

To sum up, the clearance rates of warts with the use of intralesional bleomycin are approximately 20–90% after one or more treatment sessions, with most studies reporting a positive response rate of approximately 65–85% ²². Pain from bleomycin injection typically lasts for one to two days and is followed by tissue necrosis with the formation of a black eschar ²³. Other complications including vasospasm and Raynaud's phenomenon ¹⁹, local urticaria, and permanent dystrophy or loss of nails (in periungual warts) ¹⁹ have limited its use. Furthermore, 37.5% of cases fail, and many plantar warts recur after bleomycin tattooing alone ²¹. Therefore, we decided to investigate the effectiveness of the concurrent use of bleomycin tattooing combined with TCA and shaving in the management of treatment-resistant plantar warts.

MATERIALS AND METHODS

The present cross-sectional study was conducted

in 2018 in Isfahan, Iran. Patients with plantar warts were recruited if they had not recovered with at least a six-month course of conventional treatment, including those with recurrence or those with plantar warts that clinically seemed resistant. Pregnant and lactating women, patients with immunodeficiency and those with Raynaud's phenomenon, those with medication allergies or any medication complications, those migrating to remote regions, and those who were inaccessible were excluded. The participants were briefed about the stages and methods of the study and were asked to sign an informed consent form. Then, the patients' data were recorded in a form, including the patient's details, age at onset of lesions, duration of the disease, previous treatments, and severity and type of lesions. The treatment procedure was as follows. First, the wart site was anesthetized by local infiltration of 1% lidocaine under the lesion, and the wart site was shaved with a surgical blade and tattooed with bleomycin. Bleomycin was prepared at 1 mg/ml concentration in sterile distilled water. To this end, 3 ml of sterile distilled water was added to a 15 mg vial of bleomycin to make a 5mg/ml solution of bleomycin. Then, 0.2 ml of this solution was drawn into a 1 ml insulin syringe. Next, sterile distilled water was added to make the volume of 1 ml. This solution was applied on the wart surface and was injected into the wart via the rapid multiple puncture technique with an insulin syringe needle (40 times needling per 5 mm² of wart surface). Next, 50 g of TCA crystal was

dissolved in 100 ml of distilled water to prepare a 50% TCA solution. This was used topically and was allowed to dry. This treatment was repeated at one-month intervals for a maximum of four times if it failed. The maximum amount of bleomycin per injection did not exceed 1 ml, and the total amount of the four injections never exceeded 4 ml. The patients were advised to revisit in case of complications; otherwise, the visits remained at one-month intervals. In these visits, the patients' data forms were completed according to photographs (monthly photos taken of lesions) and careful examinations. If patients responded completely to the treatment, they would be followed for six months. To this end, they were advised to revisit if any lesion occurred in the site of treatment and were also called after six months for investigating recurrence. Data were analyzed in SPSS-26 using analysis of variance (ANOVA), the chi-squared test, and Fisher's exact test at a significance level of $P < 0.05$.

RESULTS

In the present study, 60 patients with treatment-resistant plantar warts underwent treatment with bleomycin tattooing combined with TCA and shaving. Four (6.7%) were excluded for loss to follow-up, and 56 patients (93.3%) in total were assessed, of whom 32 (57.1%) were men and the rest were women. In terms of age, 44 (78.5%) patients were under 30 years of age and the rest were over

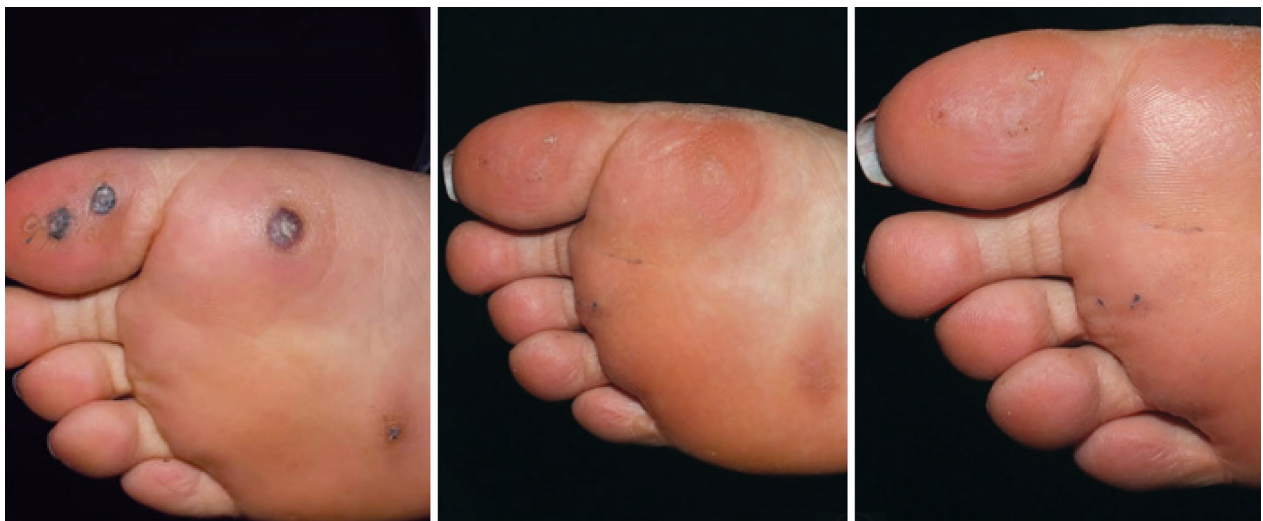

Figure 1. A 28 years old woman after first and second time treatment.

30 years, with a mean age of 25.75 ± 12.22 years. The mean interval between onset of disease and visit for treatment was 0.669 ± 8.76 years. The patients' previous treatments were as follows: surgery in 14 patients (25%), laser therapy and cryotherapy in six (10.7%), compounding formulas in two (3.6%), bleomycin tattooing in 32 (57.1%), and shaving in two (3.6%). Of these, 48 patients (85.7%) had recovered, and 14.3% had not fully recovered. A complete response to treatment was observed in 30 men (93.75%) and 18 women (75%), with a significant difference between them. Men had 1.25 times better response to treatment than

women (CI: 0.976-1.601, $P = 0.047$, OR = 1.25) (Figures 1-3).

Thirty-six patients (81.8%) under 30 years of age and 12 (100%) over 30 years had a complete response to treatment, although the difference between them was not significant ($P = 0.111$). The patients were assessed according to their monthly visits, and the decision for re-treatment was made based on the examination of the wart. The patients were treated in a maximum of four sessions. The mean frequency of treatment was 2.5 ± 1.2 times. Twelve patients (21.4%) recovered after the first treatment; 14 (25%) needed the second treatment,

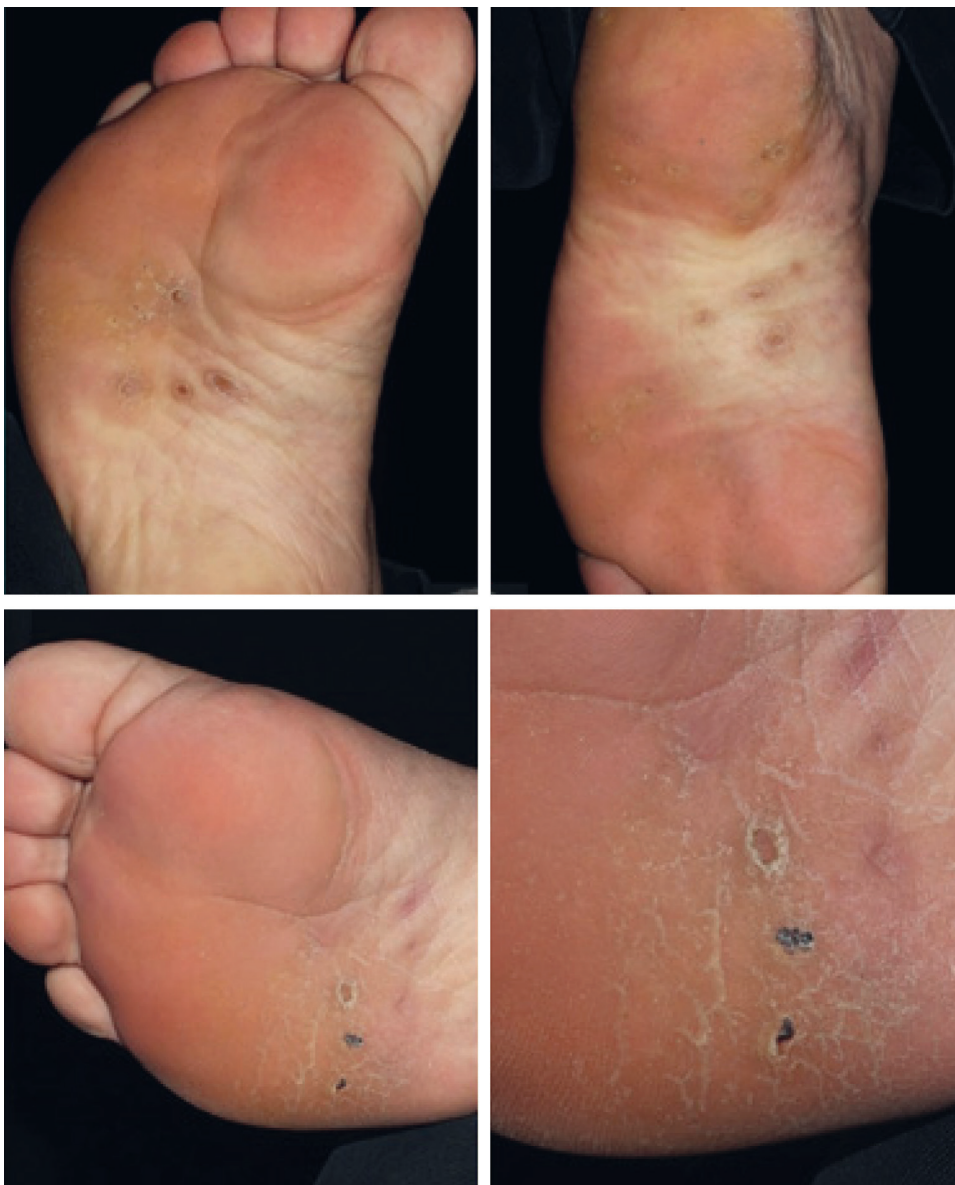

Figure 2. A 54 years old man after first and second time treatment.

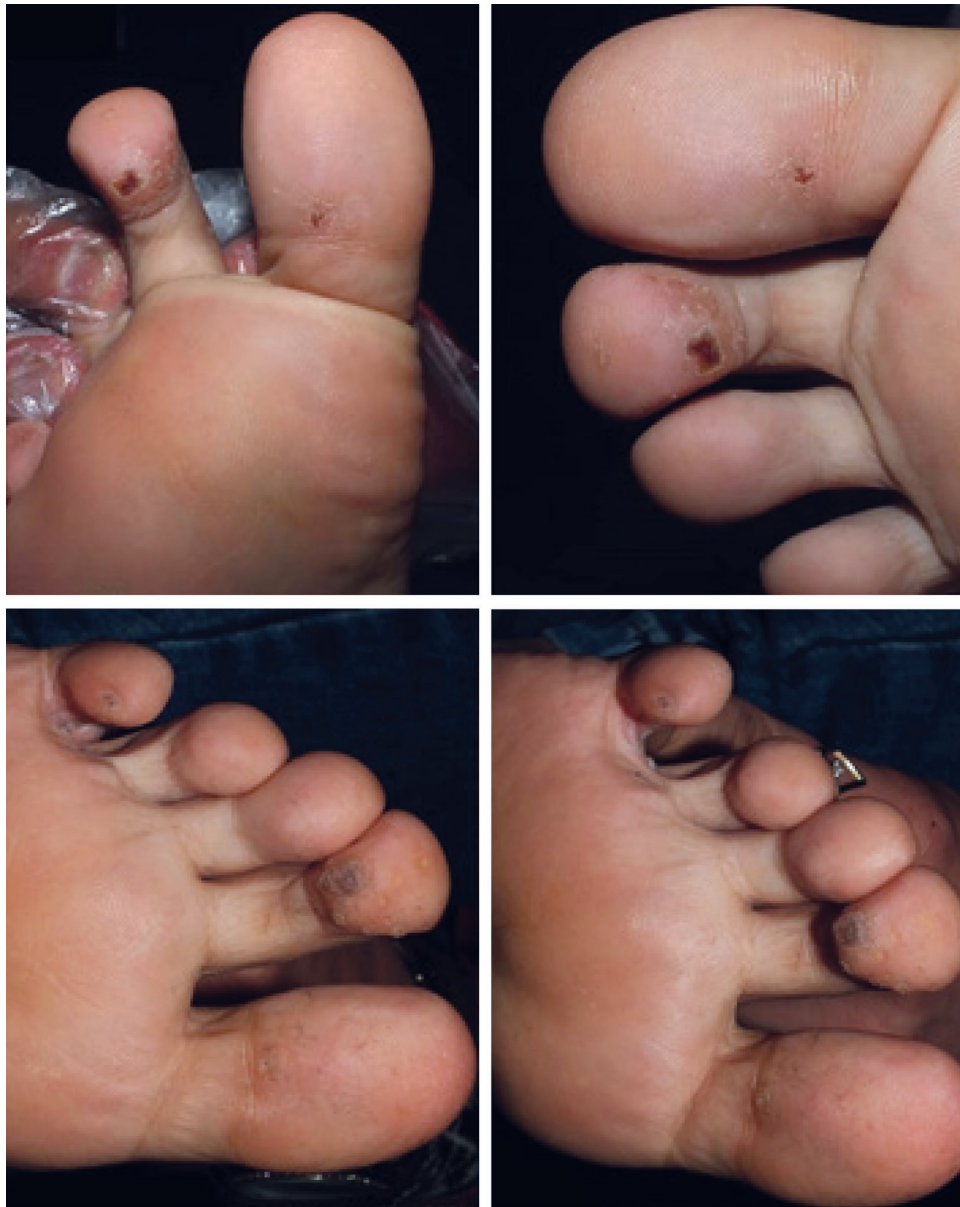

Figure 3. A 25 years old woman after first and second time treatment.

12 (21.4%) needed the third, 10 (17.9%) the fourth, and eight (14.3%) did not recover after the fourth treatment. The recovery rate was 21.4% with one treatment, 45.4% with two, 66.8% with three, and 85.7% with four (Figure 4).

Table 1 shows that the rate of response to treatment was associated with the type of previous treatments, such that patients with previous bleomycin tattooing and surgery responded better to treatment than those with a history of cryotherapy. However, there was no significant relationship between treatment response rate and the interval

between onset of disease and visits. Of all cases, five patients (8.9%) suffered recurrences: three cases (60%) were over 30 years and two (40%) were under 30 years. No significant relationship was found between recurrence rate and age ($P = 0.903$). Among the patients with recurrence, three (60%) were men and two (40%) were women ($P = 0.903$). Moreover, the recurrence rate had no significant relationship with the type of initial treatment ($P = 0.819$), the interval between onset of disease and treatment ($P = 0.246$), and the frequency of treatment ($P = 0.547$).

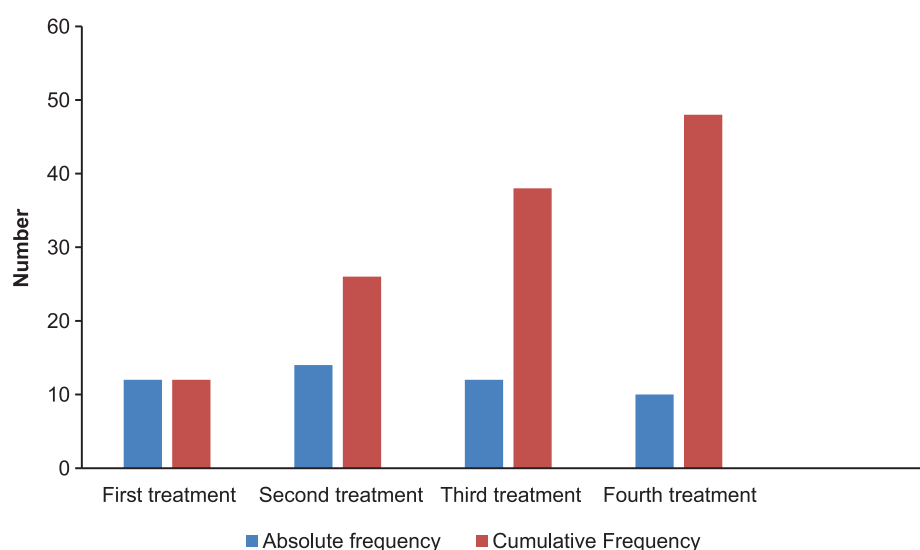


Figure 4. The absolute and cumulative frequency of patients who recovered in terms of frequency of treatment sessions

Table 1. The relationship between patient recovery and patient characteristics

	Recovery Frequency (%)		Significance level*
	Yes	No	
Age group (years)			
≤10	2 (50.0%)	2 (50.0%)	0.111
10-20	16 (100.0%)	0 (0.0%)	
20-30	18 (75.0%)	6 (25.0%)	
30-40	8 (100.0%)	0 (0.0%)	
40≤	4 (100.0%)	0 (0.0%)	
Interval between age at onset and age at first visit (years)			
≥1	18 (81.8%)	4 (18.2%)	0.503
≤1	30 (83.3%)	4 (16.7%)	
Previous treatments			
Compounding formulas	2 (100.0%)	0 (0.0%)	0.002
Bleomycin tattooing	28 (87.5%)	4 (12.5%)	
Surgery	14 (87.5%)	2 (12.5%)	
Cryotherapy	4 (66.7%)	2 (33.3%)	

DISCUSSION

Treatment-resistant plantar warts cause considerable discomfort for the patients. Furthermore, treatments have not shown a high recovery rate, rather displaying a relatively high recurrence rate. The intralesional injection of bleomycin has generally produced favorable outcomes for common warts, colloids, hypertrophic wounds, and even propranolol-resistant hemangiomas. However, most studies have focused on the bleomycin treatment of common warts. The present study investigated the effect of bleomycin tattooing combined with TCA and shaving on treatment-resistant plantar warts. Many studies

have demonstrated the high response of common warts to intralesional bleomycin compared with cryotherapy²⁵⁻²⁸. This is probably due to the endophytic nature of the lesions, which makes plantar warts tougher and insufficiently penetrable by bleomycin¹⁷.

In the present study, the response to treatment was 85.7%, displaying a significant relationship with gender (higher in men than that in women) but not with age. The recurrence rate was 8.9%, which had no significant relationship with age, gender, type of initial treatment, or frequency of treatments.

In a study by Aziz Jalali *et al.*²⁴, the effect of intralesional injection of bleomycin on resistant

warts was investigated. The researchers reported that 126 patients (97%) out of 130 responded to treatment, among which 95 (73%) were cured and 31 (24%) were relatively cured. There were 27 cases of plantar and palm warts, of which 25 responded to treatment. In total, the number of patients who recovered was 32 (24.6%) with the first injection, 44 (33.8%) with the second, and 19 (14.6%) with the third. In a study by Salk *et al.*¹⁸, the recovery rate was 87% after two injections. Moreover, Price²⁵ reported the effectiveness of this treatment modality as 47.6% after the first injection, 38.8% after the second, and 9.8% after the third. Iraj *et al.*²⁶ reported the response rate to bleomycin tattooing as 83.5% in treatment-resistant warts. There were 16 treatment-resistant plantar warts, of which 62.5% were cured, 10% recovered after the first injection, 50% after the second, and 40% after the third. Munn *et al.*²⁷ also reported a recovery rate of 92%.

Al-Naggar *et al.*²⁸ reported similar effects of micropen needling and local injections of intralesional bleomycin on plantar warts ($P = 0.474$), though tattooing was less painful than injections (20% vs 100%) ($P = 0.001$). Ryu *et al.*²⁹ administered intralesional bleomycin by micropen needling, which had a similar response rate to cryotherapy ($P = 0.474$) but was less painful (VAS: 0.48 ± 0.5 Vs 7.29 ± 0.13 ; $P < 0.001$). However, Munkvad *et al.*³⁰ reported a significantly higher response rate in the placebo group relative to the bleomycin with jet injector group ($P = 0.018$), but the authors provided no particular explanation. In a study by E Hassan *et al.*³¹, the recovery rate was 73.1% with cryotherapy and 87.6% with bleomycin injections ($P < 0.001$).

Considering the above studies, intralesional bleomycin injections appear to yield a high rate of recovery, but the patients have to bear considerable discomfort because of the pain and possible complications. Thus, we used bleomycin tattooing, which had a high rate of recovery alongside fewer side effects and less pain. Previous studies reported a high recurrence rate for treatment-resistant warts, whereas the overall recurrence rate was 8.9% in the present study. Our results showed that compared with other methods, bleomycin combined with shaving and TCA yields a high rate of recovery while causing little discomfort to the patient, with a low recurrence rate and no evidence of side effects.

CONCLUSION

The combination of bleomycin, TCA, and shaving can be an appropriate alternative to other therapeutic modalities for treatment-resistant plantar warts.

Conflict of Interest: None declared.

REFERENCES

1. Habif TP. Clinical dermatology: a color guide to diagnosis and treatment. St Louis: Mosby; 2015.
2. Stehr-Green PA, Hewer P, Meekin GE, et al. The aetiology and risk factors for warts among poultry processing workers. *Int J Epidemiol.* 1993;22(2):294-8.
3. Van Haalen FM, Bruggink SC, Gussekloo J, et al. Warts in primary schoolchildren: prevalence and relation with environmental factors. *Br J Dermatol.* 2009;161(1):148-52.
4. Westert GP, Schellevis FG, de Bakker DD, et al. Monitoring health inequalities through general practice: The Second Dutch National Survey of General Practice. *Eur J Public Health.* 2005;15(1):59-65.
5. Griffiths C, Barker J, Bleiker TO, et al, editors. Rook's textbook of dermatology. London, UK: John Wiley & Sons; 2016.
6. Thomas KS, Keogh-Brown MR, Chalmers JR, et al. Effectiveness and cost-effectiveness of salicylic acid and cryotherapy for cutaneous warts: an economic decision model. *Health Technol Assess.* 2006;10(25):iii, ix-87.
7. Gibbs S, Altman DG, Harvey I, et al. PapersLocal treatments for cutaneous warts: systematic review commentary: Systematic reviewers face challenges from varied study designs. *BMJ.* 2002;325(7362):461.
8. Cengiz FP, Emiroglu N. An open, comparative clinical study on the efficacy and safety of 10% trichloroacetic acid, 25% trichloroacetic acid and cryotherapy for verruca plana. *Cutan Ocul Toxicol.* 2015;34(2):144-8.
9. Lewis TG, Nydorf ED. Intralesional bleomycin for warts: a review. *J Drugs Dermatol.* 2006;5(6):499-504.
10. Saitta P, Krishnamurthy K, Brown LH. Bleomycin in dermatology: a review of intralesional applications. *Dermatologic Surgery.* 2008;34(10):1299-313.
11. Breathnach SM. Drug reactions in Champion RH. Burton JL, Ebling FIG. Textbook of dermatology. London, UK: Blackwell Scientific Publications;1998.
12. Androphy EJ, Butner K, Olbricht S. Human papilloma virus infection. In: Arndt KA, Leboit PE, Robinson JK, Wintroub BU. Cutaneous medicine and surgery, Philadelphia, WB Saunders Company;1996.
13. James MP, Coillier PU, Aherne W, et al. Histologic pharmacologic, immunochemical effects of injection of bleomycin into viral warts. *JAMA Dermatol.* 1993;28(6):933-7.
14. Bunney MH, Nolan MW, Buxton PK, et al. The treatment

- of resistant warts with intralesional bleomycin: a controlled clinical trial. *Br J Dermatol*. 1984;111(2):197-207.
15. Solitto RJ, Pizzano DM. Bleomycin sulfate in the treatment of mosaic plantar verrucae: a follow-up study. *J Foot Ankle Surg*. 1996;35(2):169-72.
 16. Kirby PK. Moschella and Hurley Dermatology. Philadelphia, US: WB Saunders Company; 1992.
 17. Amer M, Diab N, Ramadan A, et al. Therapeutic evaluation for intralesional injection of bleomycin sulfate in 143 resistant warts. *J Am Acad Dermatol*. 1988;18(6):1313-6.
 18. Salk R, Douglas TS. Intralesional bleomycin sulfate injection for the treatment of verruca plantaris. *J Am Podiatr Med Assoc*. 2006;96(3):220-5.
 19. Highet AS, Kurtz J. Viral infections. In: Champion RH, Burton JL, Ebling FJG (Eds). *Textbook of dermatology*. London:Blackwell Scientific Publications;1998.
 20. Iraj F, Rais Zadeh MR. Multiple puncture technique of Bleomycin therapy for recalcitrant warts. *KAUMS Journal (FEYZ)*. 2001;4(4):99-104.
 21. Sun XW, Kuhn L, Ellerbrock TV, et al. Human papillomavirus infection in women infected with the human immunodeficiency virus. *N Engl J Med*. 1997;337(19):1343-9.
 22. Sterling JC, Gibbs S, Haque Hussain SS, et al. British Association of Dermatologists' guidelines for the management of cutaneous warts 2014. *Br J Dermatol*. 2014;171(4):696-712.
 23. Herschthal J, McLeod MP, Zaiac M. Management of ungual warts. *Dermatol Ther*. 2012;25(6):545-50.
 24. Aziz-Jalali MH, Ghafarpour G, Rezaei MR, et al. Efficacy of intralesional bleomycin in the treatment of resistant warts. *J Skin Stem Cell*. 2014;1(1): e18875.
 25. Price NM. Bleomycin treatment for verrucae. *SKINmed: Dermatology for the Clinician*. 2007;6(4):166-71.
 26. Iraj F, Raieszadeh M. Treating intractable warts with intralesional injection of bleomycin by tattooing method. *J Sabzevar Uni Med Sci*. 2001;7(4):15-21.
 27. Munn SE, Higgins E, Marshall M, et al. A new method of intralesional bleomycin therapy in the treatment of recalcitrant warts. *Br J Dermatol*. 1996;135(6):969-71.
 28. Al-Naggar MR, Al-Adl AS, Rabie AR, et al. Intralesional bleomycin injection vs microneedling-assisted topical bleomycin spraying in treatment of plantar warts. *J Cosmet Dermatol*. 2019;18(1):124-8.
 29. Ryu HR, Jeong HR, Seon-Woo HS, et al. Efficacy of a bleomycin microneedle patch for the treatment of warts. *Drug Deliv Transl Res*. 2018;8(1):273-80.
 30. Munkvad M, Genner J, Staberg B, et al. Locally injected bleomycin in the treatment of warts. *Dermatologica*. 1983;167(2):86-9.
 31. Hassan E, S Hojat K, Nayyereh Amini S, et al. Comparison of therapeutic effects of intralesional injection of bleomycin and cryotherapy on common warts of hands and feet. *Iran J Dermatol*. 2006;9(4):313-8.