

Efficacy of calcipotriol in the treatment of seborrheic keratosis: a pilot study

Maryam Yousefi, MD
Leyla Nabaei, MD
Hassan Ghasemnia, MD
Ehsan Abolhasani, MD
Rayhaneh Rahgoshai, MD
Behrooz Barikbin, MD

Skin Research Center, Shahid Beheshti University of Medical Sciences, Tehran, Iran

*Corresponding Author:
Behrooz Barikbin, MD
Skin Research Center, Shahid Beheshti University of Medical Sciences, Shohada-e-Tajrish Hospital, Shahr-dari St, Tajrish Sq, Tehran, Iran
Email: bbarikbin@yahoo.com*

Conflict of interest: none to declare

*Received: 5 October 2013
Accepted: 25 November 2013*

Background: Seborrheic keratosis is a common benign tumor and many modalities are used to treat it. No convincing data favors the therapeutic effect of calcipotriol on seborrheic keratosis. We aimed to assess the efficacy of calcipotriol in the treatment of this tumor.

Method: Eligible patients aged over 40 years with seborrheic keratosis (size: 5-15mm) were instructed to apply 50µg/g calcipotriol ointment twice a day for 12 weeks. The size of the tumor was measured at baseline and after the 12-week period. The size change and improvement were assessed.

Result: Thirty out of fifty screened patients were eligible for the study and completed the 12-week course of the study. The mean baseline size of the tumors was 9.30±2.95 mm that decreased to the mean size of 2.02±1.94 mm (P<0.05). The mean percent of improvement was 80.46±17.66% and 6 patients demonstrated 100% improvement. The mean percent of improvement revealed no difference between male and female participants. An intermediate negative correlation existed between the tumor size and the improvement. No serious side effects were reported by patients.

Conclusion: Our study concluded that calcipotriol might be effective and safe in the treatment of seborrheic keratosis tumors with slightly better outcomes in smaller tumors. Controlled studies with larger sample sizes should be performed in order to find the effect of calcipotriol on this dermatologic entity.

Keywords: calcipotriol, seborrheic keratosis, topical administration, vitamin D analogues

Iran J Dermatol 2013; 16: 132-136

INTRODUCTION

Seborrheic keratosis is a benign tumor that is composed of keratinocytes. Its incidence increases by aging. It affects both males and females equally. Although it is the leading benign tumor diagnosed by the dermatologists, there is not an overall prevalence rate and different prevalence rates have reported in different populations^{1,2}.

Different modalities have been used to treat seborrheic keratosis. Removing tumors by liquid nitrogen cryosurgery is considered as the standard

treatment³, but some adverse effects like scarring and hypopigmentation are seen frequently in this modality⁴. During recent years, the tendency toward removing dermatologic tumors by laser surgery has increased and it is considered as an alternative therapeutic option⁵⁻⁷. However, due to the patients' enthusiasm in topical treatments, the search is going on to find topical therapies³.

Calcipotriol is one of the latest vitamin D analogues introduced for topical treatment of dermatologic tumors. The efficacy and safety of this preparation is fully demonstrated in psoriasis

and numerous dermatologic diseases⁸⁻¹⁶; however, there is not enough information on the effect of calcipotriol on the treatment of seborrheic keratosis. We conducted this study in order to assess the safety and efficacy of calcipotriol in improving seborrheic keratosis tumors in a small number of patients in a before/after clinical trial.

PATIENTS AND METHODS

This before/after clinical trial was conducted in Shohada-e-Tajrish and Logman-e-Hakim University Hospitals during the years 2007 and 2008. The study protocol was designed in accordance with the Helsinki declaration. The study was initiated after the university ethics committee approved it.

Patients with seborrheic keratosis attending the dermatologic clinics were assessed for participation in the study. Patients who were over 40 years of age with pathologically diagnosed seborrheic keratosis tumors measured 5-15mm who had no comorbid dermatologic problems were included in the study. Patients with a history of previous application or contraindication of vitamin D derivatives, pregnant or lactating women, or patients with any morbidity that interfered with the course of therapy were excluded. Informed consent was taken from all participants.

For patients with multiple lesions, only the largest lesion was considered as the target of treatment. Calcipotriol was applied as a 50µg/gr ointment on the tumor. Patients were instructed to apply the calcipotriol ointment twice a day for a period of four months. If the tumor disappeared during this period, calcipotriol was no longer continued. In order to prevent the undesirable

effects of calcipotriol on serum calcium levels, the maximum amount of the ointment used by the patients was monitored to be less than 100 gr weekly; however, higher doses are demonstrated to increase efficacy due to the reasonable safety margin¹⁷. Photographs were taken from tumors by a digital camera at baseline and at the end of the study period or when the tumors completely disappeared. In order to assess tumor alleviation during treatment, a standard ruler was used to measure the tumor diameter.

The decrease in the tumor diameter was assessed by statistical software. Improvement in the tumor size was described as percentage and the results were categorized in accordance with this percentage to more than 80%, between 40 and 79%, between 10% and 39%, and less than 10% improvement. Adverse effects were assessed using a questionnaire which had to be filled by the patient and physician in each session.

Data was analyzed using SPSS for windows version 13 (SPSS Inc., Chicago, IL, USA). Paired samples t-test was used to assess the improvement in the tumor size after performing Kolmogorov-Smirnov Z test for baseline data. Pearson correlation coefficient was used to assess the correlation between the primary tumor size and the improvement percentage. In all tests, the level of statistical significance was considered less than 0.05 ($P < 0.05$).

RESULTS

From 50 patients assessed for entering the trial, 30 patients including 10 males (33.3%) and 20 females (66.7%) were included and completed the

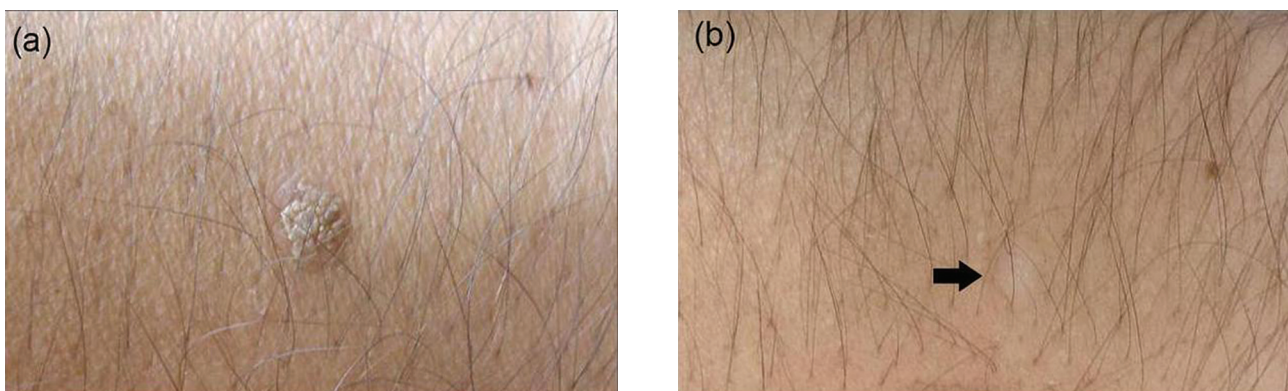


Figure 1. Seborrheic keratosis lesion on the back of a 55-year-old man; (a) before and (b) 12 weeks after applying topical calcipotriol

Table 1. Baseline and final tumor size categorized with regard to percentage of decreases in tumor size

Improvement in tumor size	(n)	Baseline tumor size (mm)	Post-treatment size (mm)	Improvement (%)
		Mean (SD)	Mean (SD)	Mean (SD)
All participants	30	9.30 (2.95)	2.02 (1.94)	80.46 (17.66)
male	10	8.00 (2.87)	1.70 (2.71)	82.61 (27.90)
Females	20	9.95 (2.83)	1.48 (2.02)	79.39 (10.19)
Complete healing	6	6.33 (1.03)	0	100
male	5	6.40 (1.11)	0	100
Females	1	6	0	100
> 80% decrease in size				
Including complete healing	23	8.69 (2.60)	1.17 (0.86)	87.75 (7.89)
male	8	7.12 (2.10)	0.50 (0.75)	93.84 (8.86)
Females	15	9.53 (2.50)	1.53 (0.69)	84.51 (5.11)
Excluding complete healing	17	9.53 (2.48)	1.59 (0.56)	83.43 (3.09)
male	3	8.33 (3.05)	1.33 (0.58)	83.57 (4.69)
Females	14	9.78 (2.39)	1.64 (0.57)	83.40 (2.89)
40-79% decrease in size	6	11.66 (3.50)	4.25 (1.47)	64.07 (2.55)
male	1	14	5	64.29
Females	5	11.20 (3.70)	4.10 (1.59)	64.02 (2.85)
10-39% decrease in size				
male	1	9	8	11.11
females	-	-	-	-

course of treatment successfully. The mean age of the participants was 52.7 ± 14.04 years (range: 27-83 years). The mean baseline tumor size was 9.30 ± 2.95 mm (min: 5; max: 15). After treatment, the mean tumor size decreased to 2.02 ± 1.94 mm (min: 0; max: 8) which the change of lesion size was significant ($P < 0.0001$). The mean percent of improvement was $80.46 \pm 17.66\%$ (min: 11.11%; max: 100%). The mean improvement percentage was 82.61 ± 27.90 and 79.39 ± 10.19 in males and females, respectively with no significant difference between them ($P = 0.73$). In 23 patients (76.7%), more than 80% improvement in the tumor diameter was seen with complete healing in 6 patients (Figure 1). More information is available in table 1.

An intermediate negative correlation was found between the size of the primary tumor and improvement (Pearson correlation coefficient = -0.396 , $P = 0.30$). Only two patients (6.7%) developed drug adverse reactions that were minor side effects (erythema and itching); these patients had no serious problems and continued the treatment.

DISCUSSION

In our study, calcipotriol showed considerable efficacy in decreasing the size of seborrheic keratoses tumors, and smaller tumors improved slightly more in contrast to larger ones. Patients complained of a

few tolerable side effects, which makes calcipotriol a good choice in treatment of seborrheic keratosis. Although calcipotriol is successfully used in the treatment of numerous diseases including extragenital lichen sclerosus¹¹, Grover's disease¹², lichen planus⁸, Reiter's syndrome¹⁵, ichthyoses¹⁰, and vitiligo¹⁴, we could only find a few previous study that investigated the effects of calcipotriol on seborrheic keratosis. In a study by Herron et al³, the standard cryosurgery was compared with several topical medications including tazarotene and calcipotriol. They reported clinical improvement in patients treated by cryosurgery or tazarotene application twice a day; however, they reported no clinical improvement with calcipotriol 0.005% ointment once or twice a day which is in contrast to our results. Mitsuhashi et al¹⁷ used calcipotriol in the treatment of seborrheic keratosis and reported more than 80% to complete resolution in 30% of the cases. Our study revealed a higher rate of improvement with more than 80% decrease in the lesions size in more than 76% of the lesions. However, the sample size of our study was smaller than the study performed by Mitsuhashi et al.

The maximal effect of calcipotriol in the treatment of psoriasis has been demonstrated to be at the concentration of $50 \mu\text{g/g}$ in previous trials^{18,19}; however, due to a cyclopropane group at the end of its molecule side chain, calcipotriol is metabolized

rapidly, which makes it an appropriate choice for topical use and safe administration in higher concentrations in contrast to other vitamin D derivatives²⁰. We used the same concentration in seborrheic keratosis treatment and a few side effects were observed.

In vitro and in vivo studies have demonstrated the limiting effect of vitamin D3 on malignant cells growth of prostate, breast, colorectal, head/neck, pancreas and lung cancer and its association with an increase in G0/G1 arrest, inducing apoptosis and differentiation, and modulating expression of growth factor receptors^{21,22}. In vitro studies have shown the inhibitory effect of vitamin D3 on keratinocytes proliferation while it can simultaneously stimulate their differentiation²³ or can induce keratinocytes apoptosis²⁴. From the results of our study and the study conducted by Mitsuhashi et al¹⁷, the effect of calcipotriol on the regression of seborrheic keratosis, a benign skin tumor, can be explained by induction of apoptosis in keratinocytes.

One limitation of our study was the lack of a control group. Another limitation was the small sample size. Calcipotriol was an expensive medication which was imported in small amounts. Therefore, we decided to limit our participants and conduct this pilot study. Inclusion of a larger population and recruiting a control group was postponed until the results of this pilot study confirmed the efficacy of this drug in treatment of seborrheic keratosis.

In conclusion, although calcipotriol demonstrated no serious side effects and was an effective therapy in our patients, further controlled studies with larger populations should be conducted to introduce calcipotriol as an option in the treatment of seborrheic keratosis.

Support

The study was conducted by the fund provided by skin research center, Shahid Beheshti University of Medical Sciences, Tehran, Iran.

REFERENCES

1. Memon AA, Tomenson JA, Bothwell J, Friedmann PS. Prevalence of solar damage and actinic keratosis in a Merseyside population. *Br J Dermatol* 2000;142:1154-9.

2. Yeatman JM, Kilkenny M, Marks R. The prevalence of seborrheic keratoses in an Australian population: does exposure to sunlight play a part in their frequency? *Br J Dermatol* 1997;137:411-4.
3. Herron MD, Bowen AR, Krueger GG. Seborrheic keratoses: a study comparing the standard cryosurgery with topical calcipotriene, topical tazarotene, and topical imiquimod. *Int J Dermatol* 2004;43:300-2.
4. Kee CE. Liquid nitrogen cryotherapy. *Arch Dermatol* 1967;96:198-203.
5. Fitzpatrick RE, Goldman MP, Ruiz-Esparza J. Laser treatment of benign pigmented epidermal lesions using a 300 nsecond pulse and 510 nm wavelength. *J Dermatol Surg Oncol* 1993;19:341-7.
6. Fitzpatrick RE, Goldman MP, Ruiz-Esparza J. Clinical advantage of the CO2 laser superpulsed mode. Treatment of verruca vulgaris, seborrheic keratoses, lentigines, and actinic cheilitis. *J Dermatol Surg Oncol* 1994;20:449-56.
7. Mehrabi D, Brodell RT. Use of the alexandrite laser for treatment of seborrheic keratoses. *J Dermatol Surg Oncol* 1994;20:449-56.
8. Bayramgurler D, Apaydin R, Bilen N. Limited benefit of topical calcipotriol in lichen planus treatment: a preliminary study. *J Dermatolog Treat* 2002;13:129-32.
9. Darley CR, Cunliffe WJ, Green CM, et al. Safety and efficacy of calcipotriol ointment (Dovonex) in treating children with psoriasis vulgaris. *Br J Dermatol* 1996;135:390-3.
10. Kragballe K, Steijlen PM, Ibsen HH, et al. Efficacy, tolerability, and safety of calcipotriol ointment in disorders of keratinization. Results of a randomized, double-blind, vehicle-controlled, right/left comparative study. *Arch Dermatol* 1995;131:556-60.
11. Kreuter A, Gambichler T, Sauermann K, et al. Extragenital lichen sclerosis successfully treated with topical calcipotriol: evaluation by in vivo confocal laser scanning microscopy. *Br J Dermatol* 2002;146:332-3.
12. Mota AV, Correia TM, Lopes JM, Guimaraes JM. Successful treatment of Grover's disease with calcipotriol. *Eur J Dermatol* 1998;8:33-5.
13. Oranje AP, Marcoux D, Svensson A, et al. Topical calcipotriol in childhood psoriasis. *J Am Acad Dermatol* 1997;36(2 Pt 1):203-8.
14. Parsad D, Saini R, Verma N. Combination of PUVAsoL and topical calcipotriol in vitiligo. *Dermatology* 1998;197:167-70.
15. Thiers BH. The use of topical calcipotriene/calcipotriol in conditions other than plaque-type psoriasis. *J Am Acad Dermatol* 1997;37(3 Pt 2):S69-71.
16. Travis LB, Silverberg NB. Psoriasis in infancy: therapy with calcipotriene ointment. *Cutaneous medicine for the practitioner*. *Cutis* 2001;68:341-4.
17. Mitsuhashi Y, Kawaguchi M, Hozumi Y, Kondo S. Topical vitamin D3 is effective in treating senile warts possibly by inducing apoptosis. *J Dermatol* 2005;32:420-3.
18. Kragballe K, Beck HI, Sogaard H. Improvement of psoriasis by a topical vitamin D3 analogue (MC 903) in a double-blind study. *Br J Dermatol* 1988;119:223-30.
19. Kragballe K. Treatment of psoriasis by the topical

- application of the novel cholecalciferol analogue calcipotriol (MC 903). *Arch Dermatol* 1989;125:1647-52.
20. Mortensen JT, Lichtenberg J, Binderup L. Toxicity of 1,25-dihydroxyvitamin D3, tacalcitol, and calcipotriol after topical treatment in rats. *J Investig Dermatol Symp Proc* 1996;1:60-3.
 21. Trump DL, Hershberger PA, Bernardi RJ, et al. Anti-tumor activity of calcitriol: pre-clinical and clinical studies. *J Steroid Biochem Mol Biol* 2004;89-90:519-26.
 22. Yu WD, Ma Y, Flynn G, Muindi JR, et al. Calcitriol enhances gemcitabine anti-tumor activity in vitro and in vivo by promoting apoptosis in a human pancreatic carcinoma model system. *Cell Cycle* 2010;9:3022-9.
 23. Van de Kerkhof PC. Biological activity of vitamin D analogues in the skin, with special reference to antipsoriatic mechanisms. *Br J Dermatol* 1995;132:675-82.
 24. Mitra RS, Wrone-Smith T, Simonian P, et al. Apoptosis in keratinocytes is not dependent on induction of differentiation. *Lab Invest* 1997;76:99-107.