

Curettage and punch excision of the vascular base: an effective method for treatment of pyogenic granuloma with excellent results

Shahriar Sadr Eshkevari, MD
Soodeh Kabir, MD
Narges Alizadeh, MD
Nahid Nickhah, MD

*Department of Dermatology, Razi
Medical Center, Guilan University of
Medical Sciences, Rasht, Iran*

*Corresponding Author:
Shahriar Sadr Eshkevari, MD
Department of Dermatology, Razi
Medical Center, Guilan University of
Medical Sciences, Rasht, Iran
e-mail: dr.sadreshkevari@yahoo.com*

Conflict of interest: none to declare

*Received: 20 June 2014
Accepted: 18 August 2014*

Background: There are different treatment options with variable results for the management of pyogenic granuloma (PG). The aim of this study was to evaluate and compare the cosmetic results and recurrence rate of classic surgical excision with a novel proposed method, curettage and punch excision of the vascular stalk (C&P) in patients diagnosed as PG.

Method: Forty consecutive cases of PG (20 with hand and 20 with facial lesions) were randomized into 2 treatment groups (total excision vs. C&P). The patients were visited by another physician who was blind to the method to evaluate the recurrence of the lesions and measure the scar size.

Result: Thirty-eight cases completed the study. There was only one recurrence in the hand C&P group that was not statistically significant when compared with the hand excision group ($P < 0.05$). The mean scar size in the cases with total excision was significantly larger than the C&P group ($P < 0.001$). Also, there were no detectable scars in 72% of the cases who underwent C&P.

Conclusion: It seems that our proposed method, i.e. C&P, is an effective option in the treatment of PG with a very low recurrence rate and more favorable cosmetic results.

Keywords: curettage, punch excision, pyogenic granuloma, total excision, treatment

Iran J Dermatol 2014; 17: 91-95

INTRODUCTION

Pyogenic granuloma (PG), or lobular capillary hemangioma, is an acquired, dome-shaped, nodular, red, and friable architecture that sits above the level of the skin surface with frequent bleeding and ulceration. It mostly occurs in children and young adults with rare spontaneous regression¹⁻³. It has several uncommon variants such as satellitosis⁴, intravenous⁵, subcutaneous⁶ and eruptive⁷.

There are different treatment options for PG⁸. Complete surgical excision is the treatment of choice with the lowest recurrence rate but with many cosmetic disadvantage, leaving a linear scar larger than the primary lesion⁹.

Based on the histological structure of PG, which includes a few larger vessels which are usually venous at the base of the lesion, we conducted this study with a new technique, curettage of the bulk and punch excision of the vascular stalk (C&P), and compared the results with total excision of PG.

PATIENTS AND METHODS

This study was done during 2 years (January 2010 – December 2012). All consecutive cases of hand / facial PG who were referred to the Department of Dermatology of Razi Medical Center, Rasht, Guilan, north of Iran, were recruited in the study. Every patient with a fast-growing pedunculated vascular

lesion that bled easily with minor trauma with a size ≤ 1 cm and confirmed diagnosis of pyogenic granuloma by histopathologic findings included in this study.

Exclusion criteria were as follows: other histological diagnoses, patients on drugs that increase the susceptibility to PG, such as retinoid or protease inhibitors (topical or systemic), drugs that may have any effect on wound healing, such as corticosteroids, anticoagulants, and cytotoxic agents, diseases that interfere with the wound healing process, such as diabetes, vascular diseases, and renal failure, history of keloid or hypertrophic scar and size > 1 cm.

After case selection, the patients were divided into two groups (hand and face groups), and each group was subsequently divided into two subgroups using standard randomization blocks, based on the surgical technique that was performed for them (excision or C&P).

All of the processes were explained to the patients and written informed consent was obtained; otherwise, the patient was excluded from the study. The study was approved by the ethics committee of Guilan University of Medical Sciences. One physician performed all procedures and another physician who was unaware of the surgical method measured the scar size and the quality of patients' satisfaction at the end of the second month.

Technical procedures

Both procedures were performed under local anesthesia with lidocaine without epinephrine. In the excision group, the lesions were excised by the elliptical method with a 30-45 degree angle; then, the wound was closed by nylon sutures, using 5-0 for facial and 4-0 for hand lesions. In the C&P group, the bulk of the lesion was removed by curettage, perpendicular to the skin surface. Then, the vascular base was excised with a 3mm punch. After that, the remaining of the wound was sealed by one nylon suture, using 5-0 for facial and 4-0 for hand lesions. After applying mupirucin ointment, the site of the procedure was covered with thin sterile gauze. The surgical time span (from beginning to the end of suturing) was measured accurately by a digital chronometer and was expressed in minute. The patients were visited after one week (suture

extraction) and then monthly for two months for detection of recurrence and scar measurement.

Statistical analysis

After ensuring the normality of the quantitative variables, parametric t-test was used to analyze normally distributed variables and Mann-Whitney was used for variables with a non-normal distribution. To analyze the qualitative variables, we used chi-square and Fisher's exact tests. Data analysis was done by SPSS software version 19, and a P-value < 0.05 was considered significant.

RESULTS

Forty patients with PG (20 cases with facial and 20 cases with hand PG with a mean size of 6.2 and 6.65 mm, respectively) were enrolled in the study of whom 62.5% were male and 37.5% were females. The age of the participants ranged between 1 and 85 years with a mean age of 18.17 years. Two patients in the face group (one in the excision and another in the C&P subgroups) were excluded due to follow-up failure (Figure 1). Recurrence was seen in only one patient (5.3%) in the hand C&P group that was not statistically significant in comparison with the hand excision group ($P < 0.05$). The same was true for the two facial subgroups with no recurrence.

Immediately after procedure, the mean size of scar in excision group was considerably greater than patients in C&P group (5.8-7.44 mm in excision group with mean size of 6.62 mm versus 0.56-0.89 mm mean size of 0.72 mm in C&P group). Using of independent t-test, this difference was statistically significant ($P=0.001$). After two months, another dermatologist who was unaware of the surgical techniques visited the patients and found no detectable scar in %72 of the patients in the C&P group and in the rest of the cases, the mean size of the scar was smaller than the mean size of the primary lesions. In the excision group, detectable scar was seen in %100 of the patients with the size slightly greater than the primary lesions (Figure 1). Moreover, the mean size of scar in the excision group was considerably larger than the C&P group after 2 months (mean size of 6.62 mm in the excision group versus 2.6 mm in the C&P group). Independent t-test showed that the difference

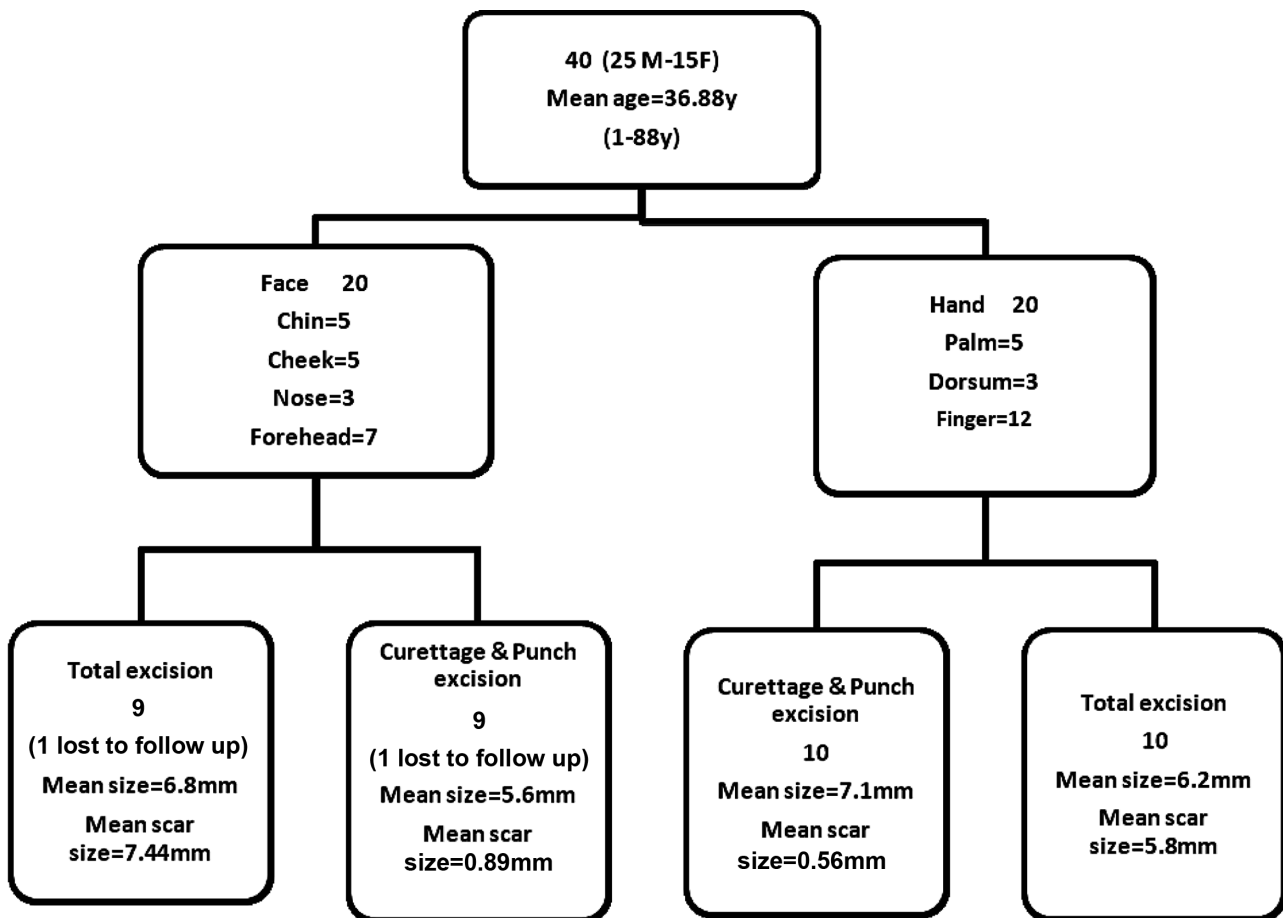


Figure 1. Demographic data, anatomic distribution, and total results of the treatment options in the groups.

was statistically significant ($P = 0.001$). Patient satisfaction at the end of the second month was analyzed by the Fisher's exact test that revealed no significant difference between the methods in hand ($P = 0.5$) or face ($P = 0.103$) groups. The result was the same, comparing both technique, anywhere performed ($P = 0.09$).

There was no significant difference in the mean time of the two procedures in face and hand groups ($P = 0.77$ and $P = 0.49$, respectively).

DISCUSSION

Pyogenic granuloma (PG) or lobular capillary hemangioma, which is neither infectious in etiology nor granulomatous in histology, is an acquired usually solitary vascular proliferation of solid collapsed capillary structures, grouped into lobules, with scant infiltrates. In its later stages, some vessels progressively transform into veins histologically. Also, a few larger vessels with smooth muscle

walls, usually venous, are often present at the base of the lesions (venous stalk)^{10,11}. The lesion grows rapidly over the course of several weeks to a final size, rarely greater than 1cm, and then stabilizes. The fingers, lips, and face are the most common affected skin sites^{3,9,10,12}.

There are at least 4 reasons for the necessity of treatment in pyogenic granuloma: discomfort, bleeding, cosmetic distress, and diagnosis. Therefore, the option that covers all these points must be regarded as the treatment of choice for PG. Traditionally, surgical excision might be the choice, but it may be associated with poor cosmetic results and a scar larger than the primary lesion⁹. Researchers have always tried to discover less invasive techniques with more favorable results; as a result, methods such as curettage & electrocautery, shave excision & cautery, cryotherapy, and laser ablation, either alone or in combination, have been utilized with different results in the recurrence rate, scarring, number of treatment sessions, and

Table 1. The rate of the recurrence and scar in different methods in some studies designed for the treatment of pyogenic granuloma

Investigator (s)	Number of cases	Recurrence rate (or failure after first session) (%)					Scar rate (%)
		Method					
		Excision	Curettage & punch (C&P)	Curettage ± Cautery	Cryotherapy	Shave & Laser	
Lee et al 2011 (review on 1950-2010) ⁽⁸⁾	1162	2.94		9.55		7.14	
Giblin et al 2007 ⁽⁹⁾	406	3.7		10.3			55
Patrice et al 1992 ⁽¹⁰⁾	176	0					
Sadr Eshkevari SH . et al 2010-12	40	0	5.3				100 28
Ghodsi et al 2006 ⁽¹³⁾	89			3 (after first session)	37 (after first session)		32.5 (Cryo) 25 (Curettage)
Mirshams et al 2006 ⁽¹⁴⁾	135				42.2 (after first session)		12.6 (overall) + 5.1 hypopigmentation

patient satisfaction ⁷⁻¹⁰.

We had no recurrence in the excision group similar to the results of a study performed by Patrice that evaluated 178 cases and Giblin who reported a recurrence rate of %3.7 in 326 patients with PG treated by excision ^{9,10}. Also, in a comprehensive review of 1162 cases of PG treated by different options, Lee reported that simple excision had the lowest recurrence rate (%2.94) when compared with other options (Table 1) ⁸. Also, we had a very low recurrence rate in the C&P group (%5.3) that was not significantly different from the excision group, indicating that our proposed technique could be a good competitor against the simple elliptical excision.

On the other hand, the most important finding of our proposed technique (C&P) was the significant absence of a visible scar (or negligible size) after two months and a detectable scar rate of 28% (smaller than the primary lesion) when compared with the 100% detectable scar rate seen in the excision. It was 55% in the study by Giblin with excision and cautery techniques ⁹. Furthermore, Mirshams reported a scar rate of 12.6% after cryotherapy and Ghodsi reported a scar rate of 25% after curettage & cautery ^{13,14} (Table 1). It should be remembered that no technique is complete and any option has positive and negative consequences; for example, while cryotherapy is an available and easy-to-perform method, it may be a more time-consuming procedure, requiring several sessions to be effective as reported by Mirshams et al ¹⁴. Also, it must be mentioned that surgical procedures have limitations as well, such as the expertise of operator that act as a crucial factor in treatment results.

With regard to the above-mentioned findings, our

proposed method, i.e. curettage & punch excision of the vascular stalk (C&P), could be considered the second choice (from the viewpoint of recurrence) and the first choice (from the viewpoint of scar rate/size and cosmetic results) amongst surgical options for the treatment of PG, covering all the above-mentioned reasons for the necessity of treatment, with a very low recurrence rate and favorable cosmetic results.

REFERENCES

1. Tritton SM, Smith S, Wong LC, et al. Pyogenic granuloma in ten children treated with topical Imiquimod. *Pediatr Dermatol* 2009;26:269-72.
2. Jafarzadeh H, Sanatkhan M, Mohtasham H. Oral pyogenic granuloma: a review. *J Oral Sci* 2006; 48:167-75.
3. Pagliai KA, Cohen BA. Pyogenic granuloma in children. *Pediatric Dermatol* 2004; 21:10-13.
4. Taira JW, Hill TL, Everett MA. Lobular capillary hemangioma with satellitosis. *J Am Acad Dermatol* 1992; 27:297-300.
5. Saad RW, Sau P, Mulvaney MP, James WD. Intravenous pyogenic granuloma. *Int J Dermatol* 1993; 32:130-2.
6. Fortna RR, Junkins-Hopkins JM. A case of lobular capillary hemangioma (pyogenic granuloma), localized to the subcutaneous tissue, and a review of the literature. *Am J Dermatopathol* 2007; 29:408-11.
7. Shah M, Kingston TP, Cotterill JA. Eruptive pyogenic granulomas: a successfully treated patient and review of the literature. *Br J Dermatol* 1995; 133:795-6.
8. Lee J, Sinno H, Tahiri Y, Gilardino MS. Treatment options for cutaneous pyogenic granulomas: a review. *J Plast Reconstr Aesthet Surg* 2011; 64:1216-20.
9. Giblin AV, Clover AJ, Athanassopoulos A, Budny PG. Pyogenic granuloma- the quest for optimum treatment: audit of treatment of 408 cases. *J Plast Reconstr Aesthet Surg* 2007; 60:1030-5.

Curettage and punch excision of pyogenic granuloma

10. Patrice SJ, Wiss K, Mulliken JB. Pyogenic granuloma (lobular capillary hemangioma): a clinicopathologic study of 178 cases. *Pediatr Dermatol* 1991; 8:267-76.
11. North PG, Kincannon J. Vascular neoplasms and neoplastic-like proliferations. In: Bologna JL, Lorzio JC, Schaffer JV. *Dermatology*. Elsevier 2012: 1923.
12. Harris MN, Desai R, Chuang TY, et al. Lobular capillary hemangiomas: an epidemiologic report, with emphasis on cutaneous lesions. *J Am Acad Dermatol* 2000; 42:1012-6.
13. Ghodsi SZ, Raziei M, Taheri A, et al. Comparison of cryotherapy and curettage for the treatment of pyogenic granuloma. *Br J Dermatol* 2006; 154: 671-5.
14. Mirshams M, Daneshpazhooh M, Mirshekari A, et al. Cryotherapy in the treatment of pyogenic granuloma. *J Eur Acad Dermatol Venereol* 2006;20:788-90.