Multiple firm, reddish-brown papules and nodules on shoulder and arm

Farideh Jowkar, MD [1]
Fatemeh Sari Aslani, MD [2]
Nasrin Saki, MD [1, 3]
Sina Kardeh, MD [1, 3]
Maryam Sadat Sadati, MD [1]

1. *Molecular Dermatology Research Center, Department of Dermatology, Shiraz University of Medical Sciences, Shiraz, Iran*
2. *Department of Pathology, Shiraz University of Medical Sciences, Shiraz, Iran*
3. *Student Research Committee, Shiraz University of Medical Sciences, Shiraz, Iran*

Corresponding Author:
Nasrin Saki, MD
Department of Dermatology, Shahid Faghihi Hospital, Zand Avenue, Shiraz, Iran
Email: nasrinsa85@yahoo.com

Conflict of interest: none to declare

Received: 20 March 2014
Accepted: 10 June 2014

The reported case is a 39-year old man who was referred to dermatology clinic with a 10 years history of multiple papules and nodules on his lateral aspect of upper shoulder and the whole right arm (Figure 1). The lesions became larger and increased in number during this period. They got painful especially on exposure to cold. He was otherwise healthy. He had no family history of any significant disease. In dermatologic physical examination, there were grouped, segmental, firm, reddish-brown papules and nodules on the lateral aspect of shoulder and the whole arm. Lesions were painful especially with deep palpation and pseudo darier sign was positive. General physical examination was normal. An excisional biopsy was done from one of the lesions.

What is your diagnosis?

Iran J Dermatol 2014; 17: 114-116

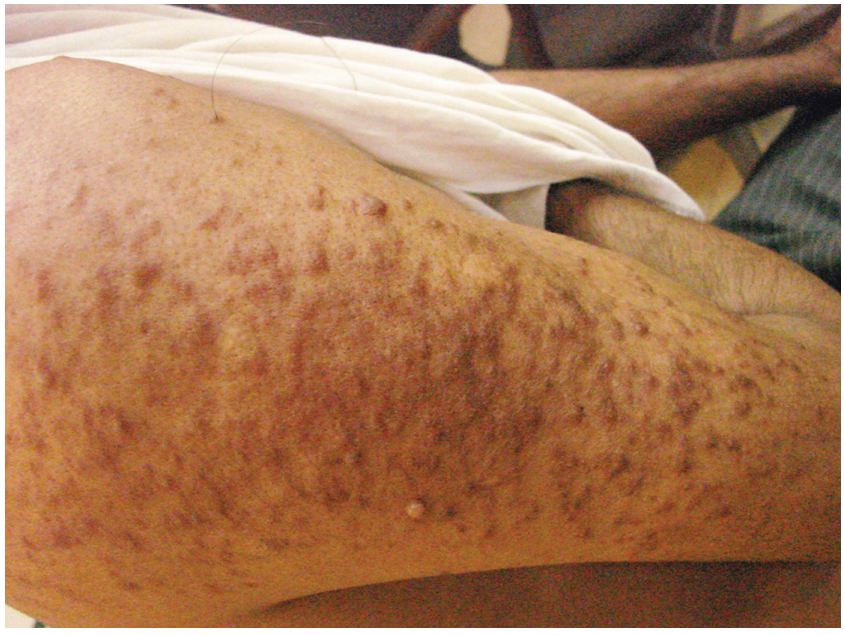

Figure 1. Multiple grouped red-brown papules in lateral aspect of shoulder

Iranian Journal of Dermatology © 2014 Iranian Society of Dermatology

Diagnosis

Dermatomal cutaneous leiomyoma

Histopathology Findings:

Histological examination showed a well-defined intradermal tumor with interlacing bundles of elongated cells with eosinophilic cytoplasm and blunt ended nuclei (Figure 2, 3). Mitotic figure was not seen. The epidermis was normal appearing.

DISCUSSION

Cutaneous leiomyomas represent benign smooth muscle tumor that can arise from arrector pilli muscles, the dartoic, vulvar or mammary smooth muscle or the muscles enveloping dermal blood vessels [1]. They are classified into solitary piloleiomyomas, multiple piloleiomyomas, both arising from arrectores pilorum muscles, solitary genital leiomyomas and angioleiomyomas [2,3]. Piloleiomyomas can be solitary or multiple and occasionally may even be hundreds. When multiple, the distribution pattern maybe clustered, linear or along blaschko lines.They usually develop on the extremities and trunk, especially in shoulder [4]. Pain can be spontaneous or on exposure to cold, pressure or trauma. Segmental cutaneous polileiomyomas has also been characterized with persistent painful cutaneous lesions and pink to violaceous, firm, tender nodules [5]. Heredity lieomyomatosis associated with renal cell carcinomas is an autosomal dominant familial syndrome characterized by the development of cutaneous and uterine leiomyoma as well as renal carcinoma most often of the papillary renal carcinoma [6]. Leiomyomas of arrector pili origin can exhibit a low mitotic activity but this does not affect the prognosis of the patient. Electron microscopic examination show that piloleiomyomas are composed of normal-appearing smooth muscle cells with central nucleus surrounded by an area containing endoplasmic reticulum and mitochondria. The cause of frequent pain or tenderness has not been determined, but the pain is a result of muscular contractions [7]. Familial cases of multiple piloleimyomas have been reported in autosomal dominant –incomplete

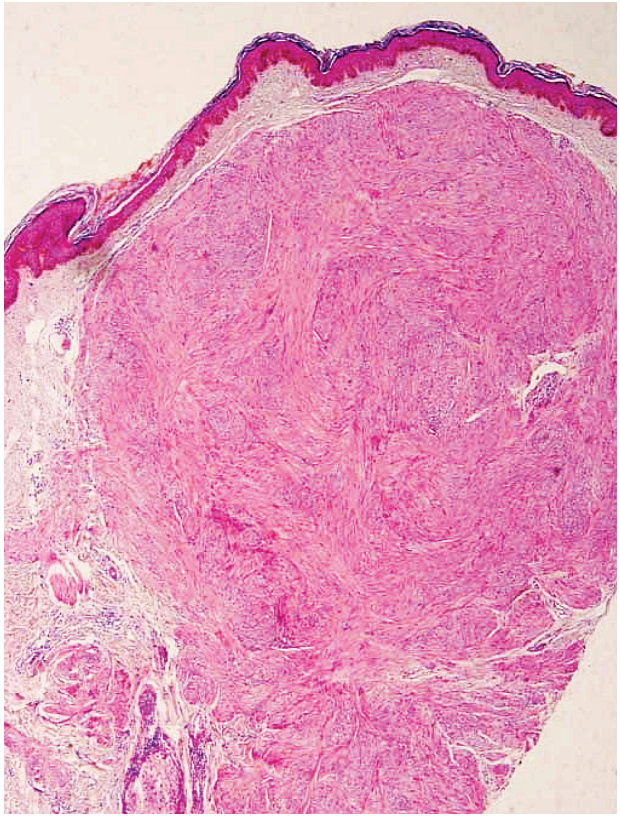

Figure 2. Well defined intradermal tumor with fascicles of eosinophilic spindle cells. (H&E ×40)

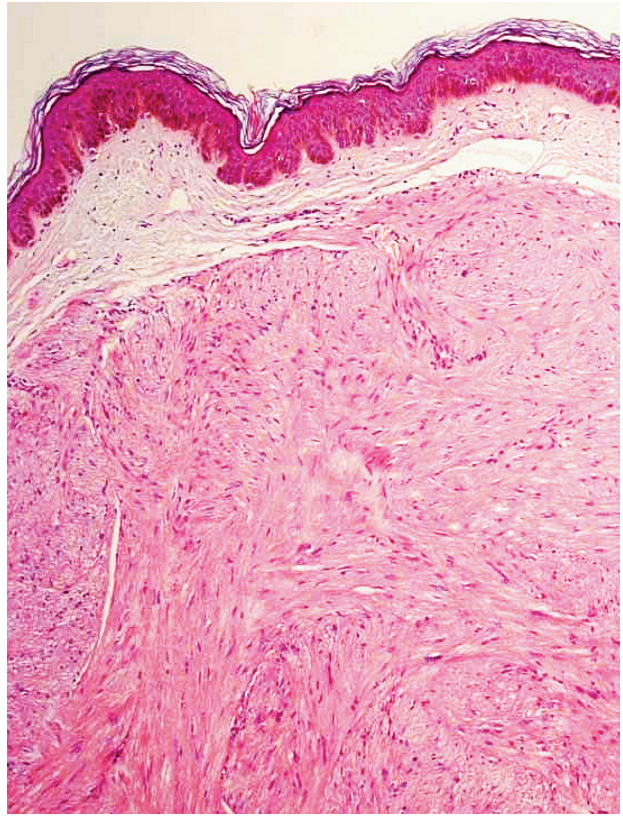

Figure 3. Interlacing bundles of eosinophilic spindle cells. (H&E ×100)

penetrance mode. Simple excision is the treatment of choice for solitary or limited tumors [4]. Gabapentin, cryotherapy or CO2 laser ablation provide relief from pain [8,9].

The present case is a 39-year old man with grouped, reddish-brown papules and nodules arising on the lateral aspect of shoulder and arm in segmental distribution. To the best of our knowledge, there are only few cases of segmental leiomyomas especially on the extremity. There was no good treatment in the reported cases. The collective experience relative to these lesions is extremely limited. Segmental leiomyoma is very rarely reported and is not yet fully known.

Acknowledgments

Authors wanted to thank Dr. Bahareh Kardeh for scientific editing of this paper.

REFERENCES

1. Fernández-Pugnaire MA, Delgado-Florencio V. Familial multiple cutaneous leiomyomas. Dermatology 1995;191: 295-8.
2. Kim GW, Park HJ, Kim HS, et al. Giant piloleiomyoma of the forehead. Ann Dermatol 2011; 23: 144-6.
3. Malhotra P, Walia H, Singh A, Ramesh V. Leiomyoma cutis: a clinicopathological series of 37 cases. Indian J Dermatol 2010; 55: 337-41.
4. Smith G, Heidary N, Patel R, et al. Cutaneous piloleiomyomata. Dermatol Online J 2009; 15: 10.
5. Cook-Norris RH, Rodriguez AO, Kovach BT, et al. Segmental cutaneous piloleiomyomata. Skinmed 2010; 8: 238-9.
6. Onder M, Adışen E. A new indication of botulinum toxin: leiomyoma-related pain. J Am Acad Dermatol 2009; 60: 325-8.
7. Kiuru M, Launonen V, Hietala M, et al. Familial cutaneous leiomyomatosis is a two-hit condition associated with renal cell cancer of characteristic histopathology. Am J Pathol 2001; 159: 825-9.
8. Christenson LJ, Smith K, Arpey CJ. Treatment of multiple cutaneous leiomyomas with CO2 laser ablation. Dermatol Surg 2000; 26: 319-22.
9. Robati RM, Rahmati–Roodsari M, Saeedi M, Maarefat A. Multiple painful nodules on the back. Iran J Dermatol 2009; 12: 33-4.