

# A Comparative Study Between 595-Nm Pulsed Dye Laser with Cutaneous Compression and Cryotherapy in the Treatment of Solar Lentigines

Hassan Seirafi, MD  
Soheil Fateh, MD  
Farshad Farnaghi, MD  
Amir Hooshang Ehsani, MD  
Pedram Noormohammadpoor, MD

Department of Dermatology, Razi Hospital, Tehran University of Medical Sciences, Tehran, Iran

Corresponding Author:  
Soheil Fateh, MD  
Department of Dermatology, Razi Hospital, Tehran University of Medical Sciences, Tehran, Iran  
Email: sfateh@razi.tums.ac.ir

Received: April 12, 2010  
Accepted: May 22, 2010

## Abstract

**Background:** Although cryotherapy is still the first-line therapy for solar lentigines, due to side effects such as post-inflammatory hyperpigmentation (PIH), especially in patients with darker skin types, pigment specific lasers should be considered as initial treatment. The aim of this study was to evaluate the efficacy and safety of cryotherapy in comparison with 595-nm pulsed dye laser (PDL) with cutaneous compression in the treatment of solar lentigines.

**Method:** Twenty two patients (skin type II- IV) with facial or hand lentigines completed this study. Lesions of one side of the face or each hand were randomly assigned and treated with either cryotherapy or PDL. Treatments were performed with radiant exposures of 10 J/cm<sup>2</sup>, 7mm spot size and 1.5ms pulse duration with no epidermal cooling. Photographs were taken before treatment and one month later. The response rate and side effects were compared.

**Results:** PDL was more likely to produce substantial lightening of solar lentigines than cryotherapy, especially in skin types III and IV (n=8, n=9; P<0.05) but might be of no difference in type II (n=5; P>0.05). PIH was only seen in the cryotherapy group. PDL group only showed minimal erythema. No purpura was observed.

**Conclusion:** PDL with compression is superior to cryotherapy in the treatment of solar lentigines in darker skin types. (*Iran J Dermatol* 2010;13: 1-5)

**Key words:** cryotherapy, compression, lentigo, pulse dye laser

## Introduction

Solar lentigines are well-circumscribed or irregularly shaped dark brown or black macules that occur on sun-exposed areas, predominantly on dorsal aspects of the hands and the face<sup>1</sup>. Because of the negative social impact on quality of life, most of the patients seek treatment.

There are two types of treatment: a) physical therapies include cryotherapy, laser therapy, intense pulsed light (IPL), and chemical peeling and b) topical therapies such as hydroquinone and tretinoin. Cryotherapy is currently the first-line therapy for solar lentigines. Although it is inexpensive and effective, side effects such as post-inflammatory hyperpigmentation (PIH) limit its use, especially in darker Fitzpatrick's skin types. Because of the broad absorption spectrum of melanin (351-1064nm), different types of laser (e.g. Pulsed Dye Laser (PDL), Q-switched ruby, Q-switched Nd:YAG)

have been used in the treatment of solar lentigines<sup>2</sup>. Although PDL is the gold standard laser treatment for many superficial cutaneous vascular lesions<sup>3</sup>, several studies suggest the good efficacy of PDL with compression in the treatment of solar lentigines<sup>4-10</sup>. To our knowledge, there are no published studies comparing cryotherapy with 595-nm pulsed dye laser (PDL) with cutaneous compression in the treatment of solar lentigines. The aim of this study was to compare the efficacy and safety of these modalities in the treatment of solar lentigines.

## Patients and Methods

Twenty four patients with Fitzpatrick's skin type II-IV with facial or hand lentigines were enrolled in this evaluator-blinded randomized clinical trial. Two patients were lost to follow-up. All patients, who completed the follow-up period, were between the ages of 28 and 67 years (mean: 51.2 years, 20

females and 2 males) and had solar lentigines on their face or hands based on clinical diagnosis. The exclusion criteria were pregnancy, recent sun tanning, previous laser or topical treatments, history of oral retinoid treatment within the previous 6 months, known photosensitivity or taking photosensitizing medication and history of vitiligo, psoriasis or keloid formation. The study protocol conformed to the ethical guidelines of the Declaration of Helsinki, and was approved by the ethics committee of our university. All patients signed informed consent forms. Lesions of one side of the face or each hand were randomly assigned and treated with either cryotherapy or 595-nm PDL (Vbeam, Candela Corp., Wayland, MA) with cutaneous compression. Treatments were performed with radiant exposures of 10 J/cm<sup>2</sup>, 7 mm spot size, and 1.5 ms pulse duration with no epidermal cooling<sup>4</sup>. During each pulse, proper compression with convex surface of a fused-silica meniscus optical element with zero optical power was used to push the blood to the outside of the laser treatment area and to prevent purpura. We used 1-3 laser passes until darkening of the lesion. Cryotherapy was done with liquid nitrogen using cryospray. The cryospray was applied for 3-5 seconds on each lesion from a distance of 3 cm from the lesion. Both procedures were well tolerated by all patients without topical anesthesia. Patients were asked to avoid sun exposure and use sunscreen on their hands and face. Before treatment and one month later, digital photographs were taken using

the same camera. Two blind observers (both board-certified dermatologists) were asked to grade each treated site (hands or face) according to 'before' and 'after' pictures. The degrees of lightening of the lentigines were graded as either poor (minimal change with lightening of 0%-25%), mild (slight improvement with lightening of 26%-50%), moderate (although quite improved, can be differentiated from the surrounding healthy skin with lightening of 51%-75%), or marked (difficult to differentiate from the surrounding healthy skin with lightening of 76%-100%). Side effects including post-inflammatory hyperpigmentation and hypopigmentation, post-PDL erythema, atrophic and hypertrophic scar were recorded in a follow-up session after one month.

Data were analyzed with SPSS 16.0 software using Wilcoxon Signed Ranks Test and Chi-Square Test. P-values of less than 0.05 was considered significant.

## Results

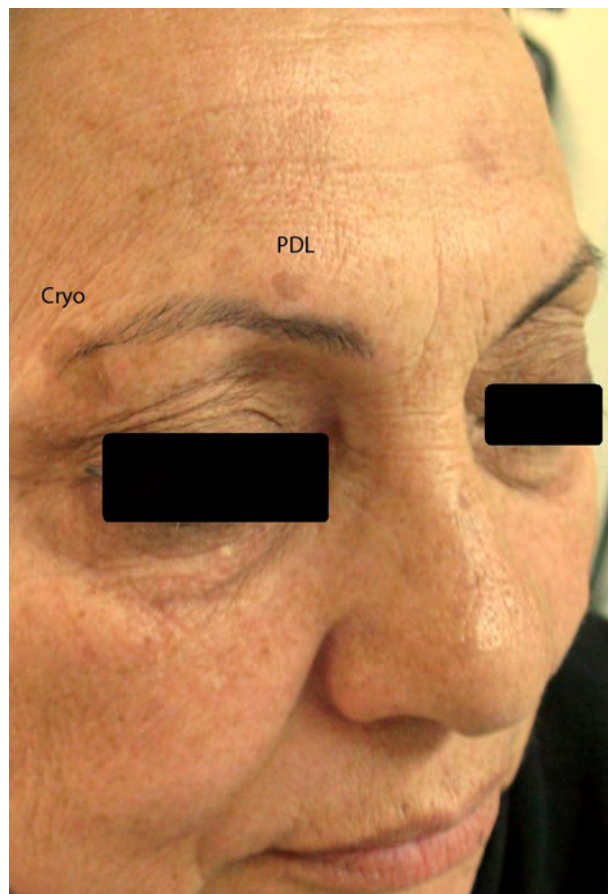
Of the 24 patients, 22 patients (20 females and 2 males) completed this study. Two female patients were lost to follow-up due to traveling issues. The frequency of Fitzpatrick's skin types were as follows: five cases (22.7%) had skin type II, eight cases (36.4 %) had skin type III and nine cases (40.9 %) had skin type IV. About two-thirds (68.2%) of the lentigines were on the dorsum of the hands and 31.8 % had lesions on the face.

**Table 1. Response to treatment in study groups**

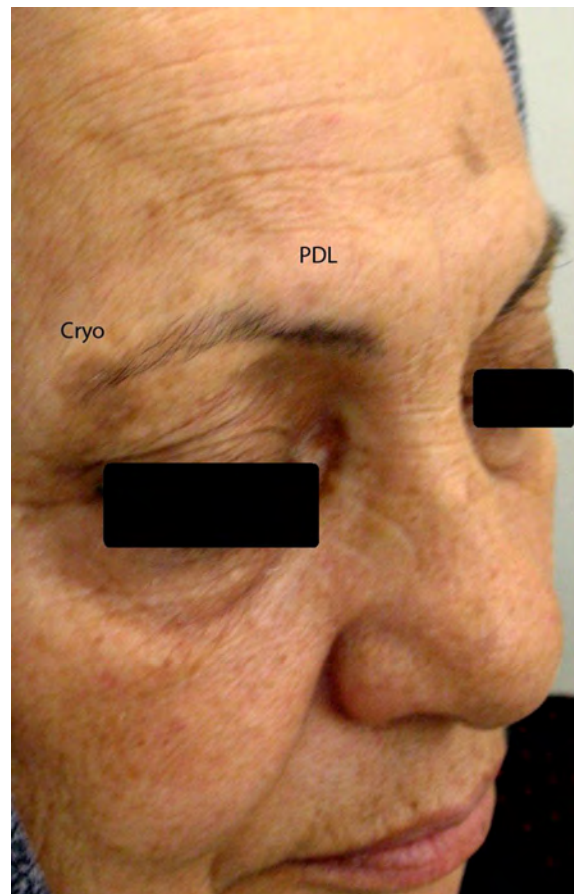
Treatment Response	Description	PDL	Cryotherapy
Poor	Minimal change with lightening of 0%-25%	2 (9.1%)	8 (36.4%)
Mild	Slight improvement with lightening of 26%-50%	3 (13.6%)	7 (31.8%)
Moderate	Though quite improved, can be differentiated from the surrounding healthy skin with lightening of 51%-75%	7 (31.8%)	5 (22.7%)
Marked	Difficult to differentiate from the surrounding healthy skin with lightening of 76%-100%	10 (45.5%)	2 (9.1%)

**Table 2. Number of the patients according to treatment response in each skin type**

Skin Type	Response	Poor	Mild	Moderate	Marked	P- value
II	PDL	0	0	4	1	0.257
	Cryotherapy	1	2	0	2	
III	PDL	0	2	1	5	0.014
	Cryotherapy	2	3	3	0	
IV	PDL	2	1	2	4	0.016
	Cryotherapy	5	2	2	0	



**Figure 1.** Two lesions on the forehead before treatment



**Figure 2.** The same lesions on the forehead one month after treatment

After one month, PDL with compression produced more than 75% lightening (marked improvement) in 10 patients (45.5%) compared to 2 patients (9.1%) in the cryotherapy group (Table 1). Statistical analysis showed a significant difference ( $P < 0.05$ , Figure 1, 2).

PDL response showed a significant difference in patients with Fitzpatrick's skin type III and IV ( $n=8$ ,  $n=9$ ;  $P < 0.05$ ). In contrast, there was no significant difference between PDL and cryotherapy response in Fitzpatrick's skin type II ( $n=5$ ;  $P > 0.05$ ) (Table 2). Side effects were only post PDL minimal erythema (after 1 month) in 6 patients (27.3%) in the PDL group and only post-inflammatory hyperpigmentation (PIH) in 8 patients (36.4%) in the cryotherapy group. There were no other side effects such as atrophic and hypertrophic scar or purpura or hypopigmentation.

## Discussion

Topical therapies for solar lentigines have fewer side effects but usually take longer than physical

therapies to achieve a good result. Lasers and cryotherapy are more popular modalities among physical therapies<sup>2</sup>. They are frequently used with an excellent clinical success rate; however, these types of therapies should be balanced against associated side effects<sup>11,12</sup>. Cryotherapy is one of the most widely used and effective treatments in this field which is inexpensive and easily accessible. The principle of treatment in cryotherapy in solar lentigines is melanocytes vulnerability to cold injury which can destroy them at temperatures of  $-4^{\circ}\text{C}$  to  $-7^{\circ}\text{C}$ <sup>2</sup>. In contrast, squamous cells can resist injury to a temperature of  $-20^{\circ}\text{C}$ <sup>11</sup>.

Melanin can absorb laser beams in a wide spectral range (351-1064nm)<sup>2</sup>. Accordingly, various types of lasers such as pulsed dye (595 nm)<sup>4-10</sup>, frequency-doubled Nd: YAG (532nm)<sup>13</sup>, KTP (532 nm)<sup>14</sup>, Q-switched ruby (694nm)<sup>8</sup>, Q-switched and long-pulse Alexandrite (755nm)<sup>14,15</sup> and Q-switched Nd: YAG (1064nm)<sup>2</sup> have been used to treat solar lentigines.

PDL has been used for vascular lesions for many years<sup>3</sup>. Recently, this laser has been used successfully for the treatment of epidermal pigmented lesions such as solar lentigines, freckles and seborrheic keratosis with some modifications<sup>4</sup>. Using skin compression during PDL removes the blood from the targeted treatment area, effectively eliminating hemoglobin as a competing target chromophore, and thereby minimizing the risk of purpura production and allowing for the use of effective radiant exposure range for treating epidermal pigmented lesions (9-10 J/cm<sup>2</sup>, 1.5 ms pulse duration)<sup>4-5</sup>. Epidermal cooling, which is usually used during the treatment of vascular lesions with PDL, decreases the interaction between laser energy and the superficial pigmented lesion<sup>4</sup>. Similar to previous studies<sup>4-10</sup>, epidermal cooling was not used in our study and no epidermal burning was recorded. Various methods of skin compression for preventing purpura have been used in previous studies. Kono et al attached a flat glass to the laser's hand-piece in their first study<sup>8</sup>. Later, they found that attaching a convex glass instead of a flat one allowed for a more uniform blood displacement during skin compression from the irradiated field and prevented purpura more effectively<sup>6</sup>. Garden et al, used the convex surface of a fused-silica meniscus optical element with zero optical power for compressing the skin during laser treatment<sup>4</sup>. By using this compression technique, no purpura was detected in our patients.

Lentigines are often treated only for cosmetic reasons. Therefore, complications in such therapeutic procedures are particularly important. Patients who have darker skins such as Asians have a higher epidermal melanin content and are more likely to develop erythema and post-inflammatory hyperpigmentation (PIH), which can be considered as a default pathophysiologic response to cutaneous injury in these patients. Several factors contribute to the development of PIH including increased melanocytic activity, dermal melanophages, and hemosiderin deposition secondary to hemorrhage. The severity of PIH is related to the degree of inflammation and extent of disruption of the epidermo-dermal junction caused by endogenous inflammatory skin disorders or iatrogenic sources such as lasers and cryotherapy<sup>8,12</sup>. We had PIH in our patients only in the cryotherapy group suggesting that the inflammatory response which is responsible for developing PIH may be more prominent in the cryotherapy group than the PDL group.

Although Q-switched Ruby and Alexandrite are highly effective in the treatment of lentigines, the risk of complications such as erythema, blistering and PIH in darker skin types (Fitzpatrick's skin type III and IV) in these lasers are higher<sup>8</sup>. Kono et al, compared Q-switched ruby laser (QSRL) versus PDL with compression for treating facial lentigines in Asians (Fitzpatrick's skin type III and IV). They found that PDL with compression was more effective than QSRL with substantially fewer side effects. PIH was detected only in some patients in the QSRL group. This study showed that PDL with compression was superior to QSRL for treating pigmented lesions in darker Fitzpatrick's skin types<sup>8</sup>. In our study, no PIH was seen in our PDL group.

Todd et al, compared 3 types of lasers (frequency-doubled Q-switched Nd: YAG laser, krypton laser and 532-nm diode-pumped vanadate laser) and cryotherapy in the treatment of solar lentigines. This study showed that laser therapy was superior to cryotherapy. Best results were achieved by Nd: YAG laser with fewest side effects<sup>13</sup>. It is difficult to directly compare these results with our study, as the types of the lasers used were different. However, similar to Todd's study, the improvement in our patients in laser group was superior to cryotherapy ( $P < 0.05$ ) with fewer side effects.

Raziee et al, compared cryotherapy versus trichloroacetic acid 33% (TCA) in solar lentigines treatment and found better results with cryotherapy. PIH was the major complication in both treatments, especially in Fitzpatrick's skin types III and IV<sup>16</sup>. In our study, we detected PIH only in the cryotherapy group, especially in darker skin types.

We conducted this pilot study to compare the efficacy and safety of a popular therapeutic modality like cryotherapy with a new laser method, PDL 595-nm with compression, in the treatment of solar lentigines. Therefore, it seems that confirming these results needs more studies with a larger population size.

Finally, it seems that the major factor in determining the therapeutic modality for solar lentigines is Fitzpatrick's skin type. In darker skin types such as skin types III and IV, there is a significant difference between PDL and cryotherapy in achieving good results. But when the patient has lighter skin types such as skin type II, there may be no difference between the two therapeutic methods. In addition, side effects in PDL with compression are minimal (only minimal erythema in a few cases without PIH or purpura) as compared to cryotherapy.

## References

1. Barnhill RL, Rabinovitz H. Solar lentigines. In: Bologna JL, Jorizzo JL, Rapini RP, editors. *Dermatology*, 2<sup>nd</sup> edn. Mosby Elsevier; 2008:1716.
2. Ortonne JP, Pandya AG, Lui H, Hexsel D. Treatment of solar lentigines. *J Am Acad Dermatol* 2006;54:S262-71.
3. Karsai S, Roos S, Hammes S, Raulin C. Pulsed dye laser: what's new in non-vascular lesions? *J Eur Acad Dermatol Venereol* 2007;21:877-90.
4. Garden JM, Bakus AD, Domankevitz Y. Cutaneous compression for the laser treatment of epidermal pigmented lesions with the 595-nm pulsed dye laser. *Dermatol Surg* 2008;34:179-83.
5. Kauvar AN, Rosen N, Khrom T. A newly modified 595-nm pulsed dye laser with compression handpiece for the treatment of photodamaged skin. *Lasers Surg Med* 2006;38:808-13.
6. Kono T, Chan HH, Groff WF, Sakurai H, Takeuchi M, et al. Long-pulse pulsed dye laser delivered with compression for treatment of facial lentigines. *Dermatol Surg* 2007;33:945-50.
7. Galeckas KJ, Collins M, Ross EV, et al. Split-face treatment of facial dyschromia: Pulsed dye laser with a compression handpiece versus intense pulsed light. *Dermatol Surg* 2008;34:672-80.
8. Kono T, Manstein D, Chan HH, et al. Q-switched ruby versus long-pulsed dye laser delivered with compression for treatment of facial lentigines in Asians. *Lasers Surg Med* 2006;38:94-7.
9. Galeckas KJ, Ross EV, Uebelhoer NS. A pulsed dye laser with a 10-nm beam diameter and a pigmented lesion window for purpura-free photorejuvenation. *Dermatol Surg* 2008;34:308-13.
10. Pootongkam S, Asawanonda P. Purpura-free treatment of lentigines using a long-pulsed 595 nm pulsed dye laser with compression handpiece: a randomized, controlled study. *J Drugs Dermatol* 2009;8:s18-24.
11. Hexsel DM, Mazzuco R, Bohn J, Borges J, Gobbato DO. Clinical comparative study between cryotherapy and local dermabrasion for the treatment of solar lentigo on the back of the hands. *Dermatol Surg* 2000;26:457-62.
12. Ho SG, Chan HH. The Asian dermatologic patient: review of common pigmentary disorders and cutaneous diseases. *Am J Clin Dermatol* 2009;10:153-68.
13. Todd MM, Rallis TM, Gerwels JW, Hata TR. A comparison of 3 lasers and liquid nitrogen in the treatment of solar lentigines. *Arch Dermatol* 2000;136:841-6.
14. Bassichis BA, Swamy R, Dayan SH. Use of the KTP laser in the treatment of rosace and solar lentigines. *Facial Plast Surg* 2004;20:77-83.
15. Trafeli JP, Kwan JM, Meehan KJ, Domankevitz Y, et al. Use of a long-pulse alexandrite laser in the treatment of superficial pigmented lesions. *Dermatol Surg* 2007;33:1477-82.
16. Raziiee M, Balighi K, Shabanzadeh-Dehkordi H, Robati RM. Efficacy and safety of cryotherapy vs. trichloroacetic acid in the treatment of solar lentigines. *J Eur Acad Dermatol Venereol* 2008;22:316-9.