

# Successful treatment of major pemphigus vulgaris relapse with mycophenolate mofetil and high-potent topical corticosteroid

Nafiseh Esmaili, MD  
Cheyda Chams-Davatchi, MD  
Maryam Daneshpazhooh, MD  
Maryam Ghiasi, MD  
Robabe Abedini, MD  
Hossein Mortazavi, MD  
Iman Roghani, MD

*Autoimmune Bullous Disease  
Research Center, Tehran University of  
Medical Sciences, Tehran, Iran*

*Corresponding Author:  
Robabe Abedini, MD  
Autoimmune Bullous Disease  
Research Center, Razi Hospital,  
Tehran University of Medical Sciences,  
Tehran, Iran*

*Conflict of interest: none to declare*

*Received: May 6, 2012  
Accepted: August 16, 2012*

**Background:** Pemphigus vulgaris (PV) is an autoimmune bullous disorder that is fatal if left untreated. High dose systemic corticosteroids are the basis of therapy. The addition of immunosuppressive agents has improved the disease outcome and reduced the required corticosteroid dose and related toxicity. Mycophenolate mofetil is increasingly used as a steroid-sparing agent in immunotherapy of PV. Herein, we tried to appraise the efficacy of mycophenolate mofetil and topical clobetasol in the control of the major relapses of pemphigus vulgaris.

**Method:** Seventeen patients with severe relapse of pemphigus vulgaris were included in this study. All patients had complete remission on/off therapy before this period of recurrence. The patients were treated with 2g/day mycophenolate mofetil and 25-35g/day topical clobetasol propionate ointment. All patients were monitored for the side effects of therapy.

**Result:** The patients were followed for a mean period of 12.7 months. The average length of time from initiating mycophenolate to 50% control (partial remission), which occurred in all patients, was  $6 \pm 1.17$  weeks. Fifteen patients achieved complete remission averagely at week  $20.8 \pm 7.70$ . The average duration of follow-up after complete disease control was 8 months (ranging from 2-13.5 months). Three patients were free of lesions for more than 12 months and 10 for more than 6 months. No important mycophenolate mofetil related complication was observed during treatment.

**Conclusion:** The combination of mycophenolate mofetil and topical corticosteroid can be used to control PV relapses and taper-off corticosteroid.

**Keywords:** clobetasol propionate, mycophenolate mofetile, pemphigus vulgaris, relapse, treatment

Iran J Dermatol 2012; 15: 33-37

## INTRODUCTION

Pemphigus vulgaris (PV) is a rare autoimmune bullous disorder that is fatal if left untreated<sup>1,2</sup>. The use of systemic corticosteroids in high doses has reduced mortality rates to less than 10%<sup>3,4</sup>. The introduction of adjuvant immunosuppressive agents

has improved the disease outcome and reduced the required corticosteroid dose and related toxicity. However, the optimal immunosuppressive agent has not yet been recognized<sup>5</sup>. Mycophenolate Mofetil (MMF) is one of these immunosuppressive drugs with which successful treatment of pemphigus vulgaris has been reported, as an adjuvant or

as monotherapy<sup>6-14</sup>. This study describes our experience of the use of MMF and topical clobetasol propionate in the management of 17 patients with severe relapse of PV without the classic increase in their low dose steroid intake.

## PATIENTS AND METHODS

### Patients

Seventeen patients with severe relapse of pemphigus vulgaris (PV) were included prospectively in this study. All of the patients had complete remission on/off therapy before this period of recurrence. The patients had not received any additional immunosuppressive therapy during the 3 months preceding the relapse and the total daily dose of oral prednisolone was  $\leq 10$  mg. Previous treatment regimens that caused remission

before the current relapse are presented in Table 1.

PV had been diagnosed on the basis of (I) clinical criteria: flaccid skin and/or mucosal blisters; (II) histological criteria: suprabasal acantholysis, leading to clefts and subsequent blistering, and eosinophilic spongiosis and (III) direct immunofluorescence: deposition of IgG, complement 3 (C3) or both on keratinocyte membranes<sup>15</sup>. All patients had contraindication(s) to high dose corticosteroids because of severe associated medical conditions (Table 1) and completed informed consent forms before the initiation of therapy. Severe relapse was defined as the occurrence of at least five cutaneous or mucosal lesions per day during the period when minimal therapy was given<sup>16</sup>.

### Treatment

The patients were treated with 2g/day

**Table 1.** Summary of demographic characterization, clinical presentation at the baseline and follow-up period

Number	Gender	Age (years)	Type	Disease period (years)	Last relapse (years ago)	Prednisolone dose (mg/day)	Clobetasol (tube/day)	Contraindication for high dose prednisolone	Number of lesions	Pemphigus severity score	Time to complete remission (weeks)	Follow-up period (months)
1	F	52	MC	10	2	0	3	Osteoporosis	14	4	16	16
2	F	46	MC	4	-	10	3.5	cataract, Hypertension, Nephrolithiasis	20	7	28	14
3	F	57	MC	1	-	0	2.5	Diabetes Mellitus	20	7	14	17
4	F	37	MC	1	-	10	3	Hypertension	38	7	16	12
5	F	30	MC	8	3	0	3.5	Necrosis of the femoral head	42	11	-	-
6	M	60	MC	6	3	10	3	Diabetes Mellitus, Congestive heart failure	45	10	24	14
7	F	40	C	8	2	8.75	2.5	Cataract	42	8	24	14
8	F	70	MC	2	2	6.25	3	Cataract, Glaucoma	24	5	16	-
9	F	76	MC	5	1	10	2.5	Hypertension, Cataract, Glaucoma	34	8	16	17
10	M	66	MC	12	1	2.5	3	Hyper tension, Cataract, Osteoporosis, Diabetes Mellitus	46	12	40	14
11	M	56	MC	6	3	7.5	2.5	Diabetes Mellitus	23	7	16	-
12	F	53	MC	3	-	5	3	Necrosis of the femoral head <sup>14</sup>	17	7	14	12
13	F	43	M	6	1	8.25	3	Hypertension, Diabetes Mellitus, Central retinal artery obstruction	10	4	16	14
14	M	33	MC	2	-	10	2.5	Peptic ulcer disease	12	5	8	10
15	F	38	MC	2	-	10	2.5	Glaucoma	38	9	-	-
16	F	52	MC	6	1	10	3	Diabetes Mellitus, Osteoporosis	16	6	24	8
17	F	45	C	15	2	0	3	Osteoporosis	11	4	12	6

C, cutaneous; M, mucosal; MC, mucocutaneous

mycophenolate mofetil (MMF: 500 mg four times per day). The clobetasol propionate ointment was initially used at the dose of 25-35 g/day. The dose was tapered 5g/day each two weeks and was discontinued after about 10-12 weeks. Oral prednisolone was maintained at the previous dose ( $\leq 10$  mg/day) until the disease was controlled. Patients who did not receive oral corticosteroids at the time of recurrence were treated with MMF alone.

**Efficacy and safety**

Clinical disease severity was assessed on the first visit according to a four-point scoring system as shown in Table 2<sup>9</sup>. For every patient, the scores were determined for each skin area/mucosal surface and summed at baseline and then at weekly intervals thereafter. At each visit, the patients were inquired about the adverse events and monitored by routine biochemical and hematological tests with a special focus on leukocyte counts. The patients were followed for at least 6 months.

Complete remission was defined as the epithelialization of all skin and mucosal lesions, partial remission as the epithelialization of more than 50% of the lesions but not of all lesions, and relapse as the occurrence of new cutaneous or mucosal erosions<sup>9</sup>.

**RESULTS**

Seventeen patients (13 females, 4 males) entered the study. The mean age of the patients was 50.18 years (ranging from 30-76 years). Fourteen patients had mucocutaneous involvement; one and two patients had only mucosal and cutaneous involvement, respectively. All included patient had

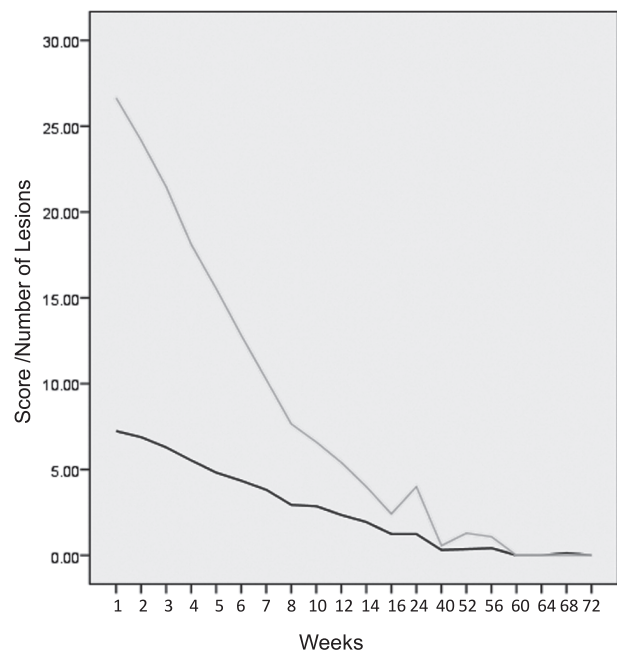
severe PV relapses when they entered the study. Before the PV relapse, all patients were in complete remission on low dose/off prednisolone therapy. The patients were receiving a mean prednisolone dosage of 6.3 mg/day (ranging from 0-10 mg) and all had at least one contraindication for high dose steroid therapy (Table 1). Clinically, they averagely had 27 (ranging from 10-46) lesions at the beginning of the study and mean pemphigus severity score (PSS) was 7.23 (ranging from 4-12).

The patients were followed for a mean period of 12.7 months (6-17 months). The average length of time from initiating MMF to 50% control (partial remission), which occurred in all patients, was  $6\pm 1.17$  weeks.

Improvement in PSS continued for all patients until week 16, after which two patients developed severe relapses (at weeks 16 and 32, respectively) on MMF and were therefore excluded from the study. Thus, fifteen patients achieved complete remission averagely at week  $20.8\pm 7.70$ . Two other patients were excluded at weeks 24 and 32 because of non-authorized discontinuation of MMF. The average duration of follow-up after complete disease control was 8 months (ranging from 2-13.5 months). Three patients were free of lesions for more than 12 months and 10 for more than 6 months (Figure 1), indicating the decline in

**Table 2.** Pemphigus severity score

Skin lesions		Mucosal lesions	
Areas of the body	Score	Involved mucosa	Score
Face	Nil: 0	Oral	Nil: 0
Scalp	Mild:1-2	Nasal	Mild:1
Nose skin	Moderate:3-5	Larynx	Moderate:2-3
Breast	Severe:6	Conjunctiva	Severe:4
Axilla		Genital	
Groin		Urethra	
thorax			
Abdomen			
Limbs			



**Figure 1.** Changes of mean Pemphigus severity score (black) and lesion numbers (gray) during treatment period.

PSS during treatment. No important MMF related complication was reported during treatment.

## DISCUSSION

Pemphigus vulgaris still has a high rate of therapy related morbidity after long periods of high-dose steroid therapy. Novel immunosuppressive agents have been introduced to spare steroids and reduce such complications. MMF is an immunosuppressive drug that was primarily applied in kidney and other organ allografts to prevent rejections<sup>17,18</sup>. It is a prodrug of mycophenolic acid (MPA), which inhibits synthesis of guanosine nucleotides<sup>18</sup>.

Because T and B lymphocytes are highly dependent on the *de novo* pathway for the production of guanosine nucleotides, MPA selectively inhibits their proliferation and antibody production. MPA also inhibits glycosylation and the expression of some adhesion molecules in lymphocytes and monocytes<sup>19,20</sup>. In treated patients, the percentages of CD38+ B cells and activated T/NK cells were reduced during therapy<sup>21</sup>.

In doses of up to 2 g/d, MMF is usually well tolerated without significant myelosuppression, hepatotoxicity, or nephrotoxicity<sup>17,18</sup>. Because of its lower toxicity profile and selective mechanism of action, MMF represents a good choice for immunotherapy. Several reports have showed successful treatment of PV with MMF in combination with high-dose prednisolone, or as monotherapy<sup>6,8,10,11,14,22,23</sup>. We also previously reported that the combination of prednisolone and MMF could be used successfully and safely in the treatment of non-generalized forms of PV<sup>9</sup>.

These studies mainly focus on the treatment of active PV or PV that is refractory to other therapies. In fact, few studies have exclusively evaluated its efficacy in the treatment of PV relapses. Mimouni et al, published a study of 31 PV patients who had relapses during prednisolone tapering or had clinically significant adverse effects from previous drug therapy. They found that remission was achieved with MMF in 22 (71%) of the patients. The median time to achieve complete remission was 9 months (range, 1-13 months)<sup>12</sup>.

We evaluated the effectiveness of MMF and topical clobetasol in the control of major relapses of pemphigus vulgaris. The PV relapses were controlled in 76% of our patients without any

increase in the prednisolone dose. Complete remission was achieved earlier (about 5 months) in our study as compared to the study conducted by Mimouni et al<sup>12</sup>.

We started MMF at the dose of 2g/day and did not observe any significant side effects. Our previous study showed an increased incidence of bacterial and viral infections in PV patients treated with the combination of MMF (2g/day) and prednisolone (2mg/kg)<sup>9</sup>. Thus, the steroid sparing effect of MMF (as shown in the current study) is significant in terms of reducing steroid-related toxicity.

Although high dose topical clobetasol has systemic effects similar to oral prednisolone<sup>24</sup>, our experience showed that the side effects of this type of therapy were insignificant. Moreover, we successfully tapered it off in 10-12 weeks.

In our series, clinical severity was ameliorated with reducing PSS (Figure 1) after introduction of MMF and topical clobetasol propionate. MMF was well tolerated and we could discontinue all the medications in 3 patients after one year. Our study showed that combination of MMF and topical clobetasol not only could control severe PV relapses but also induced long term remission in some patients.

According to our experiences, MMF may be highly effective for patients with even severe PV relapses who cannot continue high-dose systemic steroids. This therapy offers the advantage of fewer adverse effects in comparison with immunosuppressive/systemic steroid combination therapy and, therefore, is very well tolerated by patients. In a recent randomized clinical trial, patients with active PV responded to MMF quickly, and were in remission for a longer time before relapse<sup>6</sup>.

In conclusion, our study showed that the combination of MMF and topical corticosteroid could be used to control PV relapses and taper-off corticosteroid just to MMF when the patients have contraindications to high dose corticosteroids.

## REFERENCES

1. Ahmed AR, Moy R. Death in pemphigus. *J Am Acad Dermatol* 1982; 7: 221-8.
2. Savin JA. International mortality from bullous diseases since 1950. *Br J Dermatol* 1976; 94: 179-89.
3. Lever WF, Schaumburg-Lever G. Treatment of pemphigus

- vulgaris. Results obtained in 84 patients between 1961 and 1982. *Arch Dermatol* 1984; 120: 44-7.
4. Savin JA. Corticosteroids and death in pemphigus. *J Am Acad Dermatol* 1983; 9: 275.
  5. Martin LK, Werth V, Villanueva E, et al. Interventions for pemphigus vulgaris and pemphigus foliaceus. *Cochrane Database Syst Rev* 2009; (1): CD006263.
  6. Beissert S, Mimouni D, Kanwar AJ, et al. Treating pemphigus vulgaris with prednisone and mycophenolate mofetil: a multicenter, randomized, placebo-controlled trial. *J Invest Dermatol* 2010; 130: 2041-8.
  7. Chams-Davatchi C, Nonahal AR, Daneshpazooch M, et al. Open trial of mycophenolate mofetil in the treatment of resistant pemphigus vulgaris. *Ann Dermatol Venereol* 2002; 129: 23-5.
  8. Enk AH, Knop J. Mycophenolate is effective in the treatment of pemphigus vulgaris. *Arch Dermatol* 1999; 135: 54-6.
  9. Esmaili N, Chams-Davatchi C, Valikhani M, et al. Treatment of pemphigus vulgaris with mycophenolate mofetil as a steroid-sparing agent. *Eur J Dermatol* 2008; 18: 159-64.
  10. Grundmann-Kollmann M, Kaskel P, Leiter U, et al. Treatment of pemphigus vulgaris and bullous pemphigoid with mycophenolate mofetil monotherapy. *Arch Dermatol* 1999; 135: 724-5.
  11. Koga H, Ishii N, Hamada T, Karashima T, et al. Successful treatment with mycophenolate mofetil of four Japanese patients with pemphigus vulgaris. *Eur J Dermatol* 2010; 20: 472-5.
  12. Mimouni D, Anhalt GJ, Cummins DL, et al. Treatment of pemphigus vulgaris and pemphigus foliaceus with mycophenolate mofetil. *Arch Dermatol* 2003; 139: 739-42.
  13. Powell AM, Albert S, Al FS, et al. An evaluation of the usefulness of mycophenolate mofetil in pemphigus. *Br J Dermatol* 2003; 149: 138-45.
  14. Sarma N, Ghosh S. Mycophenolate mofetil as adjuvant in pemphigus vulgaris. *Indian J Dermatol Venereol Leprol* 2007; 73: 348-50.
  15. Stanley JR, Amagai M. Pemphigus, bullous impetigo, and the staphylococcal scalded-skin syndrome. *N Engl J Med* 2006; 355: 1800-10.
  16. Murrell DF, Dick S, Ahmed AR, et al. Consensus statement on definitions of disease, end points, and therapeutic response for pemphigus. *J Am Acad Dermatol* 2008; 58: 1043-6.
  17. Kitchin JE, Pomeranz MK, Pak G, et al. Rediscovering mycophenolic acid: a review of its mechanism, side effects, and potential uses. *J Am Acad Dermatol* 1997; 37: 445-9.
  18. Lipsky JJ. Mycophenolate mofetil. *Lancet* 1996; 348: 1357-9.
  19. Allison AC, Kowalski WJ, Muller CJ, et al. Mycophenolic acid and brequinar, inhibitors of purine and pyrimidine synthesis, block the glycosylation of adhesion molecules. *Transplant Proc* 1993; 25(3 Suppl 2): 67-70.
  20. Allison AC, Eugui EM. Mycophenolate mofetil and its mechanisms of action. *Immunopharmacology* 2000; 47: 85-118.
  21. Weigel G, Griesmacher A, Karimi A, et al. Effect of mycophenolate mofetil therapy on lymphocyte activation in heart transplant recipients. *J Heart Lung Transplant* 2002; 21: 1074-9.
  22. Beissert S, Werfel T, Frieling U, et al. A comparison of oral methylprednisolone plus azathioprine or mycophenolate mofetil for the treatment of pemphigus. *Arch Dermatol* 2006; 142: 1447-54.
  23. Stowd LC, Taylor SL, Jorizzo JL, et al. Therapeutic ladder for pemphigus vulgaris: Emphasis on achieving complete remission. *J Am Acad Dermatol* 2011; 64: 490-4.
  24. Joly P, Roujeau JC, Benichou J, et al. A comparison of oral and topical corticosteroids in patients with bullous pemphigoid. *N Engl J Med* 2002; 346: 321-7.